

ENT 喉科MM

A Case of Post-Radiotherapy Bilateral Vocal Fold Palsy

2025/01/21

PRESENTER: Clerk高歆嵐、劉威廷

SUPERVISOR: 洪偉誠 醫師

PATIENT PROFILE

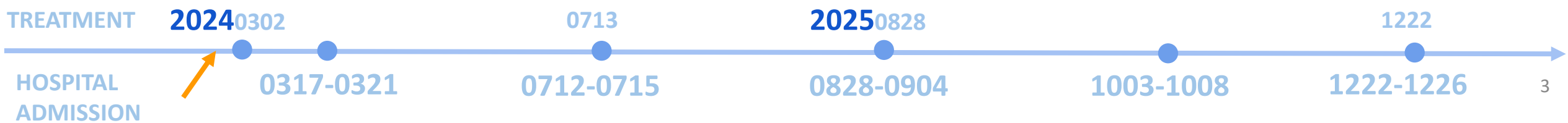
- 54-year-old, Male
- Chart NO.
- Past History:
HTN, DM poor control, Hyperlipidemia.
- ABC History:
 - Alcohol: Social consumption.
 - Betel Nut: 10 pieces/day for over 30 years.
 - Cigarettes: 2 packs PPD for 35 years.

2024/03/01 ENT OPD

CC: Hoarseness for 2 months

sore thraot(-), lumping(+), odynophagia(-), dysphagia(-)

no oral visible mass; strong gag(+)

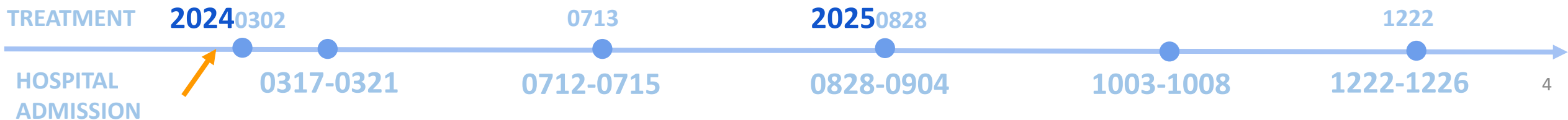
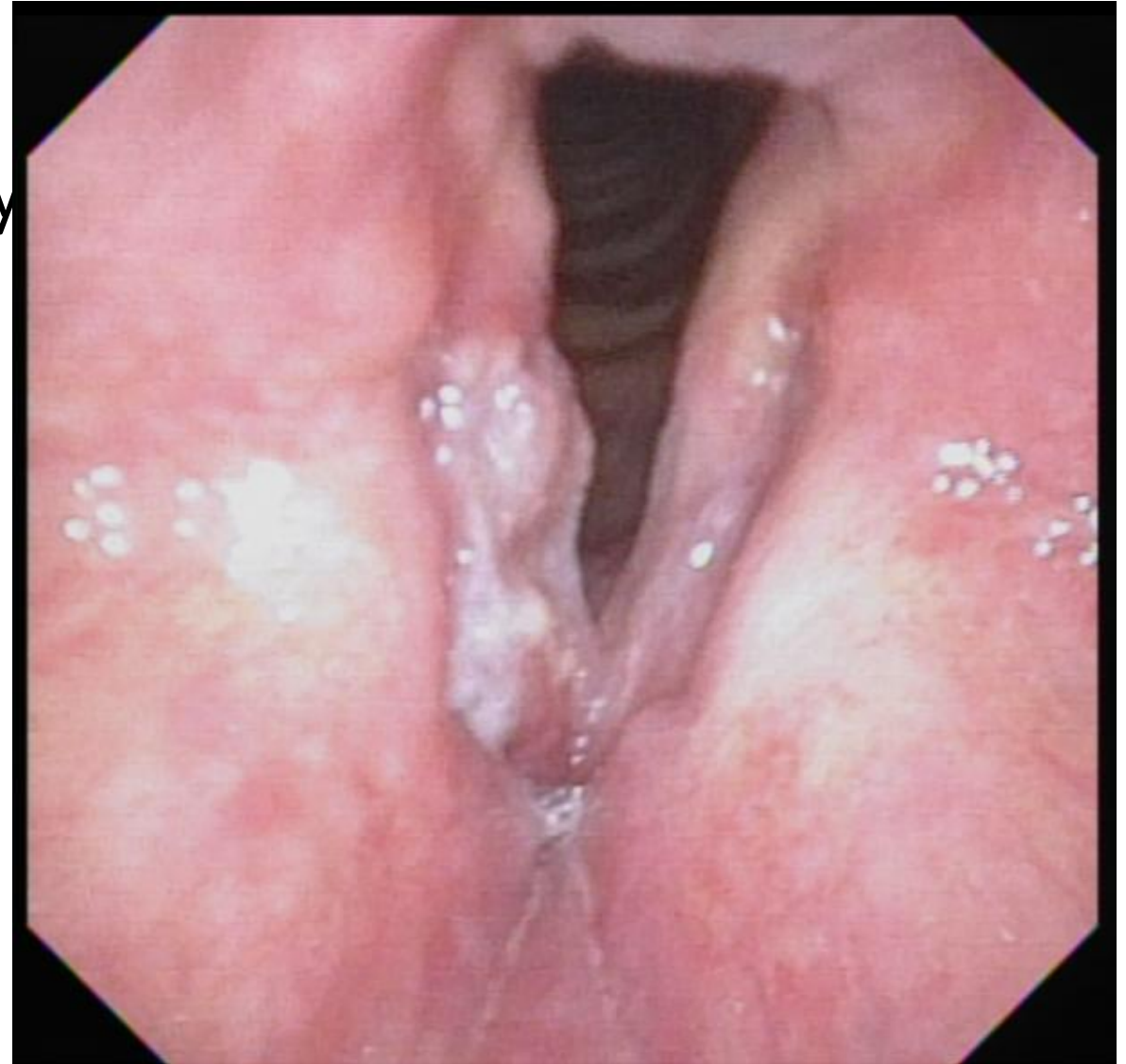

2024/03/01

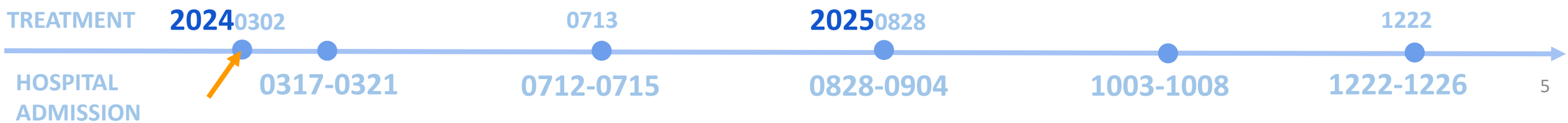
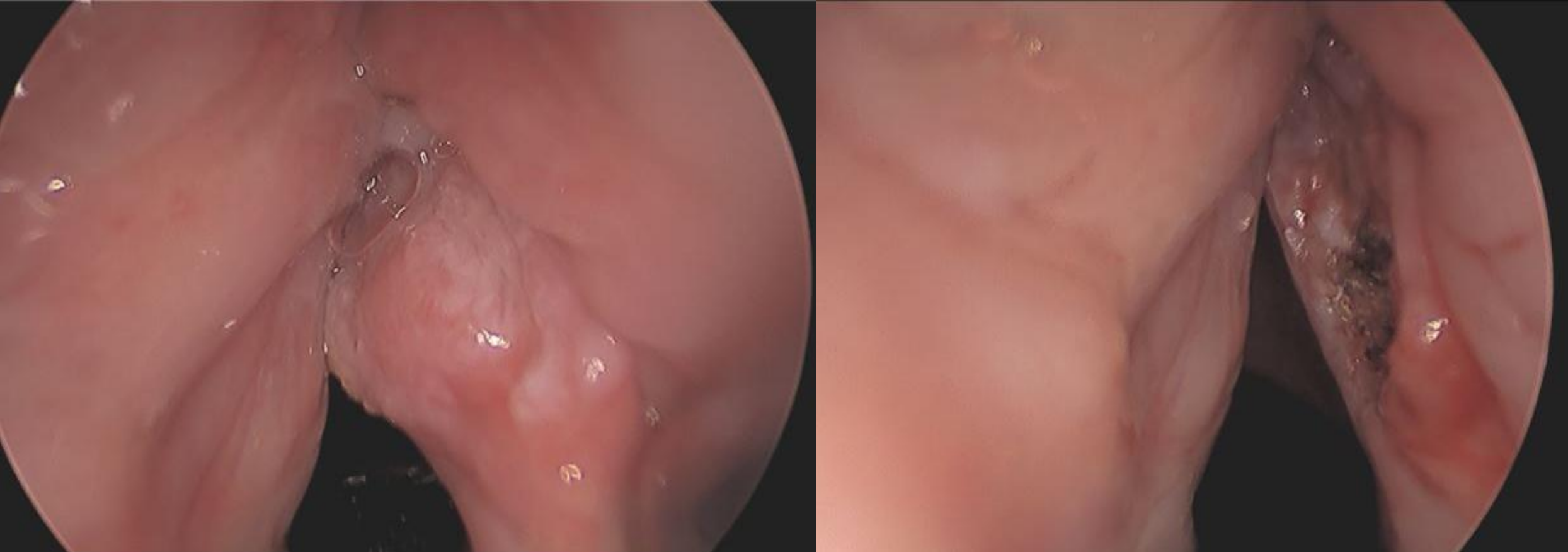
Nasopharyngolaryngoscopy

FINDING:

right VF tumor, left leukoplakia,
fair VF movement



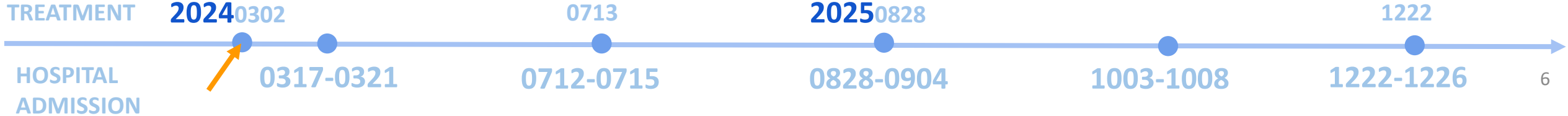
2024/03/02 LMS biopsy



2024/03/02 LMS biopsy

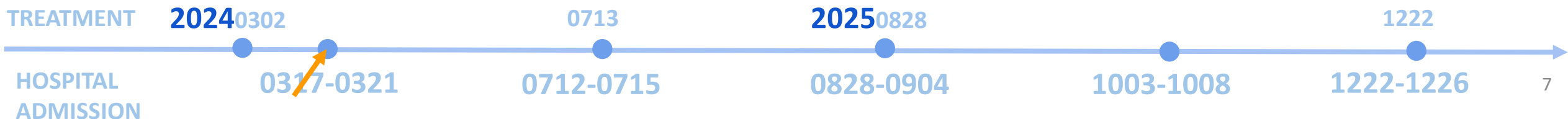
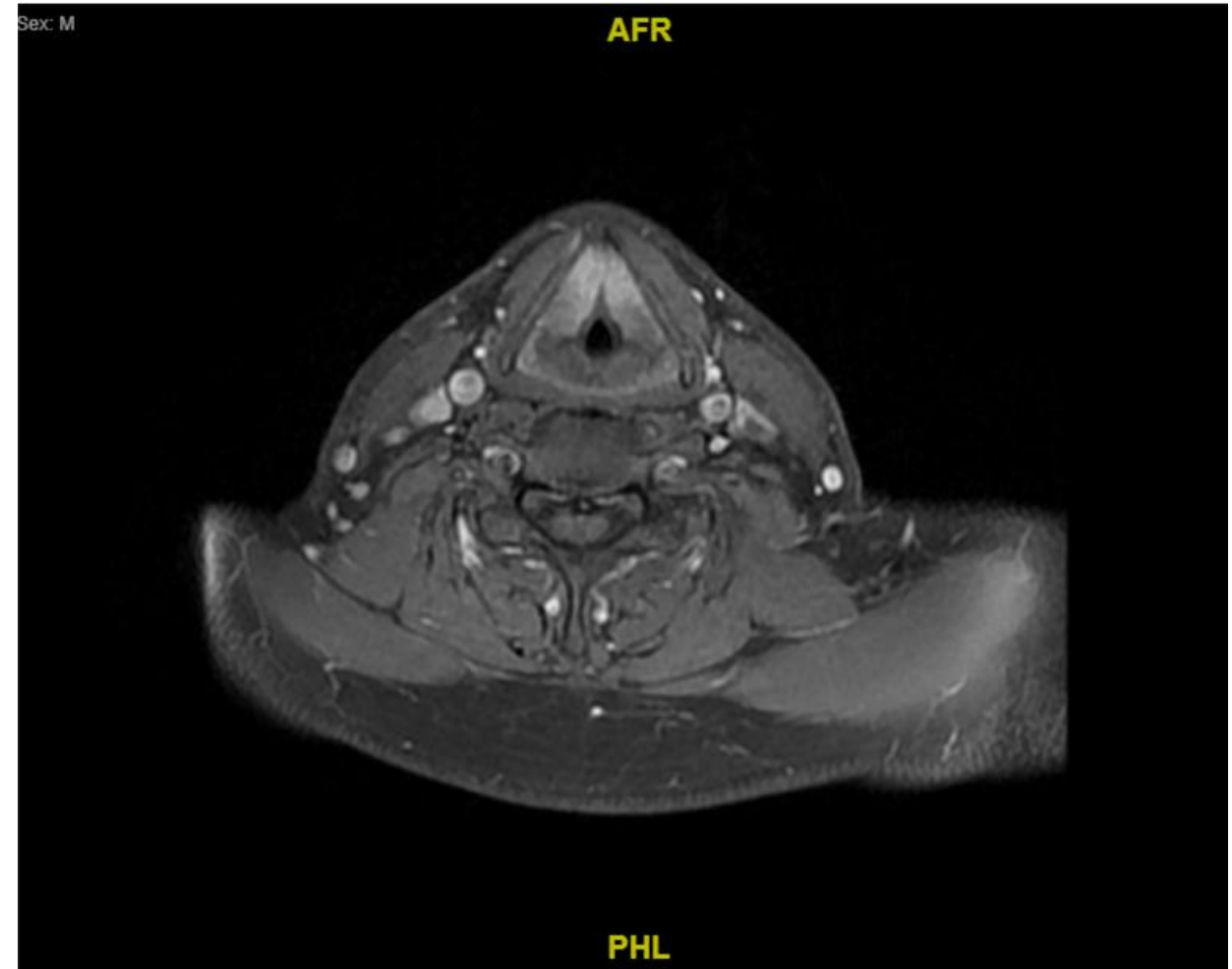
Pathology Report Impression:

Larynx, vocal fold, right, laryngomicrosurgery biopsy, **squamous cell carcinoma**



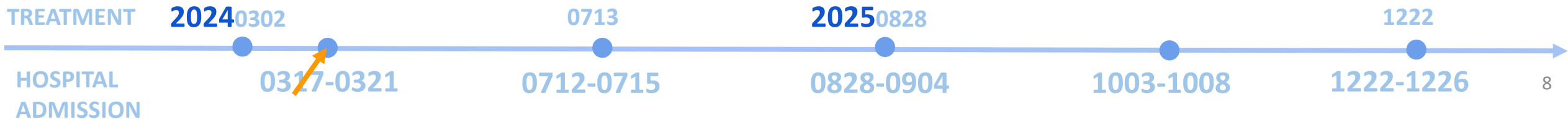
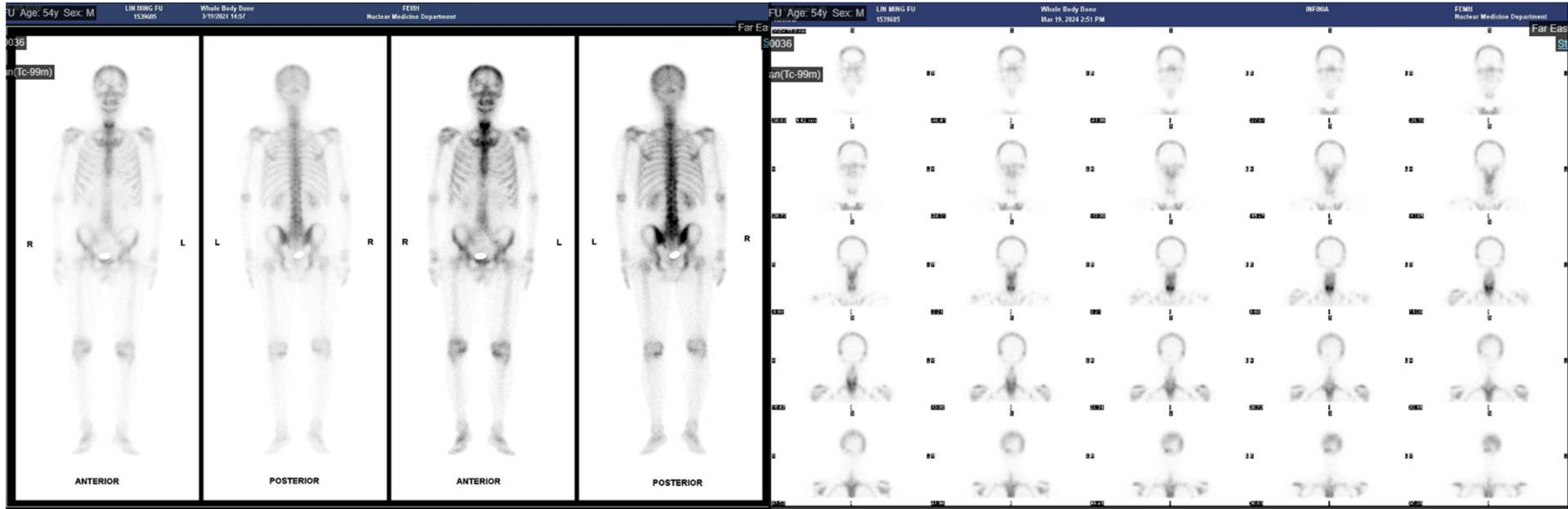
2024/03/17-21 admitted for staging work up

- MRI Neck:
No evidence of deep space invasion or thyroid cartilage destruction. No significant cervical lymphadenopathy identified on MRI.



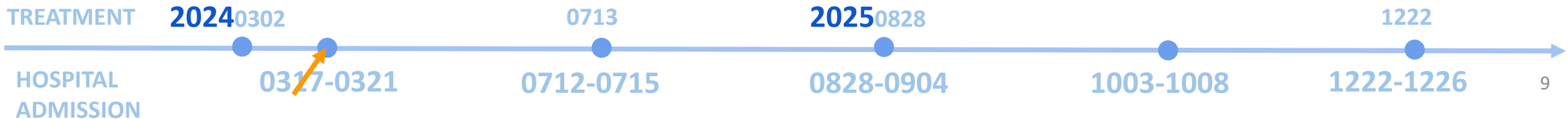
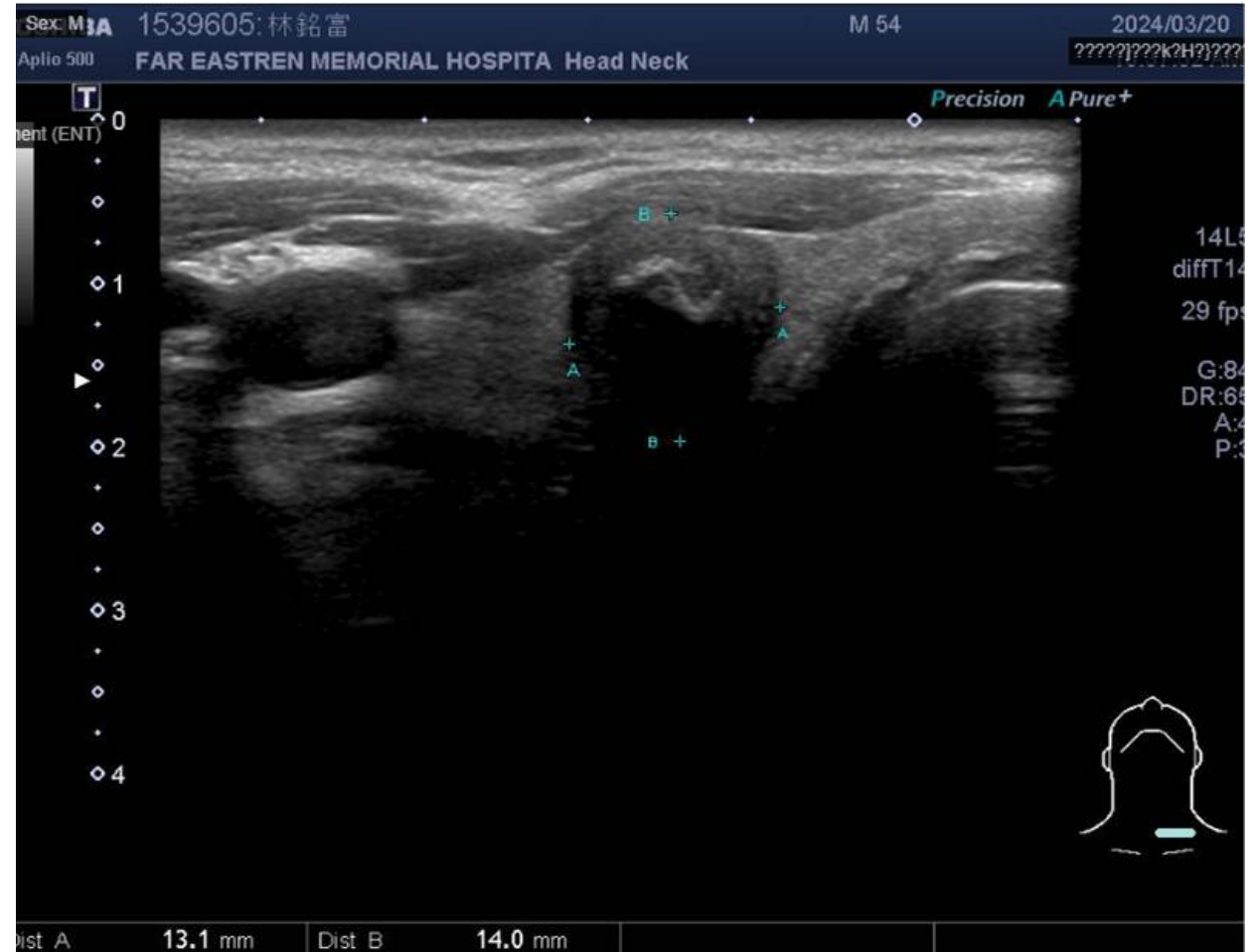2024/03/17-21 admitted for staging work up

- Chest X-ray: No suspicious pulmonary nodules or infiltrates.
- Bone Scan: No evidence of distant osteoblastic or osteolytic metastasis.



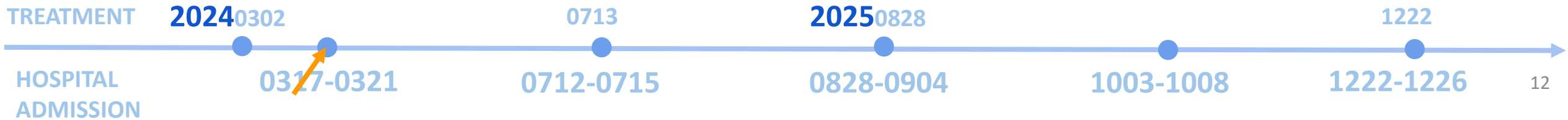
2024/03/17-21 admitted for staging work up

- **Thyroid Ultrasound & FNA:** Identified a left thyroid nodule; Cytology revealed features **suspicious for Papillary Thyroid Carcinoma (PTC).**



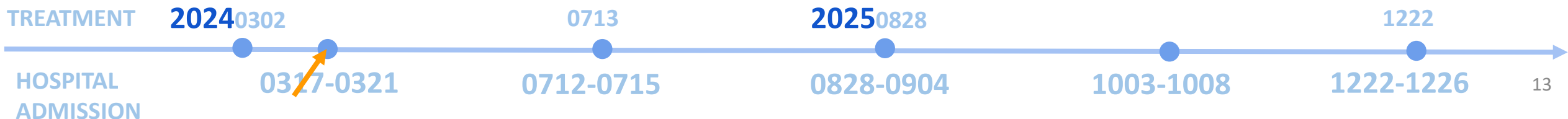
CURRENTLY DIAGNOSIS

- Glottic Squamous Cell Carcinoma of right VF, cT1N0M0, Stage I
- Suspicious Papillary Thyroid Carcinoma
- Gastric Ulcer; Duodenal Ulcer
- Type 2 Diabetes Mellitus
- Hypertension
- Hyperlipidemia



TREATMENT PLAN

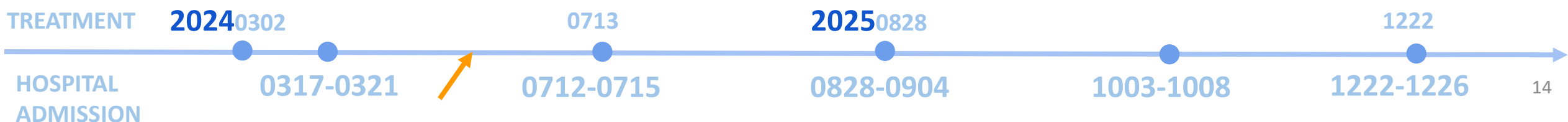
- Primary Treatment:
Organ-preservation strategy with Definitive Radiotherapy for laryngeal SCC.
- Thyroid Management:
Scheduled for Left thyroid lobectomy following the initial workup.



2024/04/08-05/15 Radiotherapy

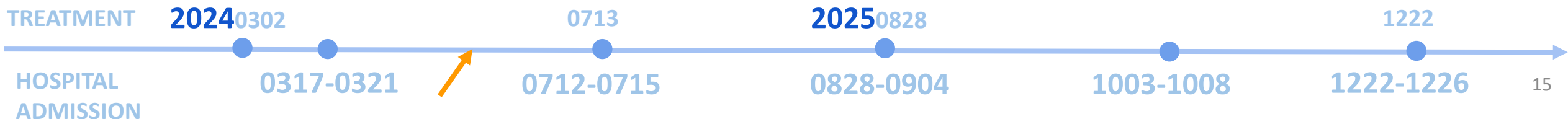
Definitive Radiotherapy for Early-stage glottic laryngeal cancer (Stage I, cT1N0M0).

- Modality: Tomotherapy with Image-Guided Radiation Therapy (IGRT).
Total Dose: **6300 cGy** (63 Gy).
Fractionation: **28 fractions** (2.25 Gy per fraction, hypofractionated scheme).
Target Volume: Larynx tumor and larynx (CTV_H).
- Acute Toxicities (CTCAE v3.0)
Dermatitis: Grade 3
Mucositis: Grade 1
Systemic: Fatigue (Grade 1), Weight loss (Grade 1).
Pain: VAS score 2 during follow-up.

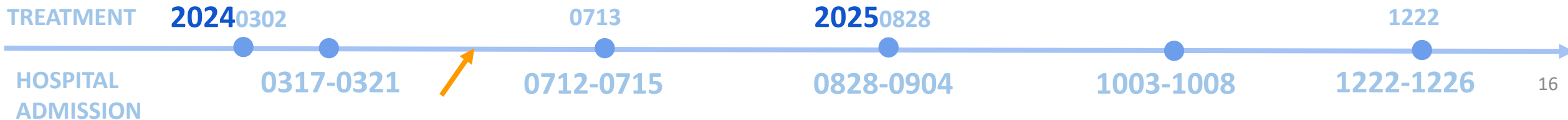
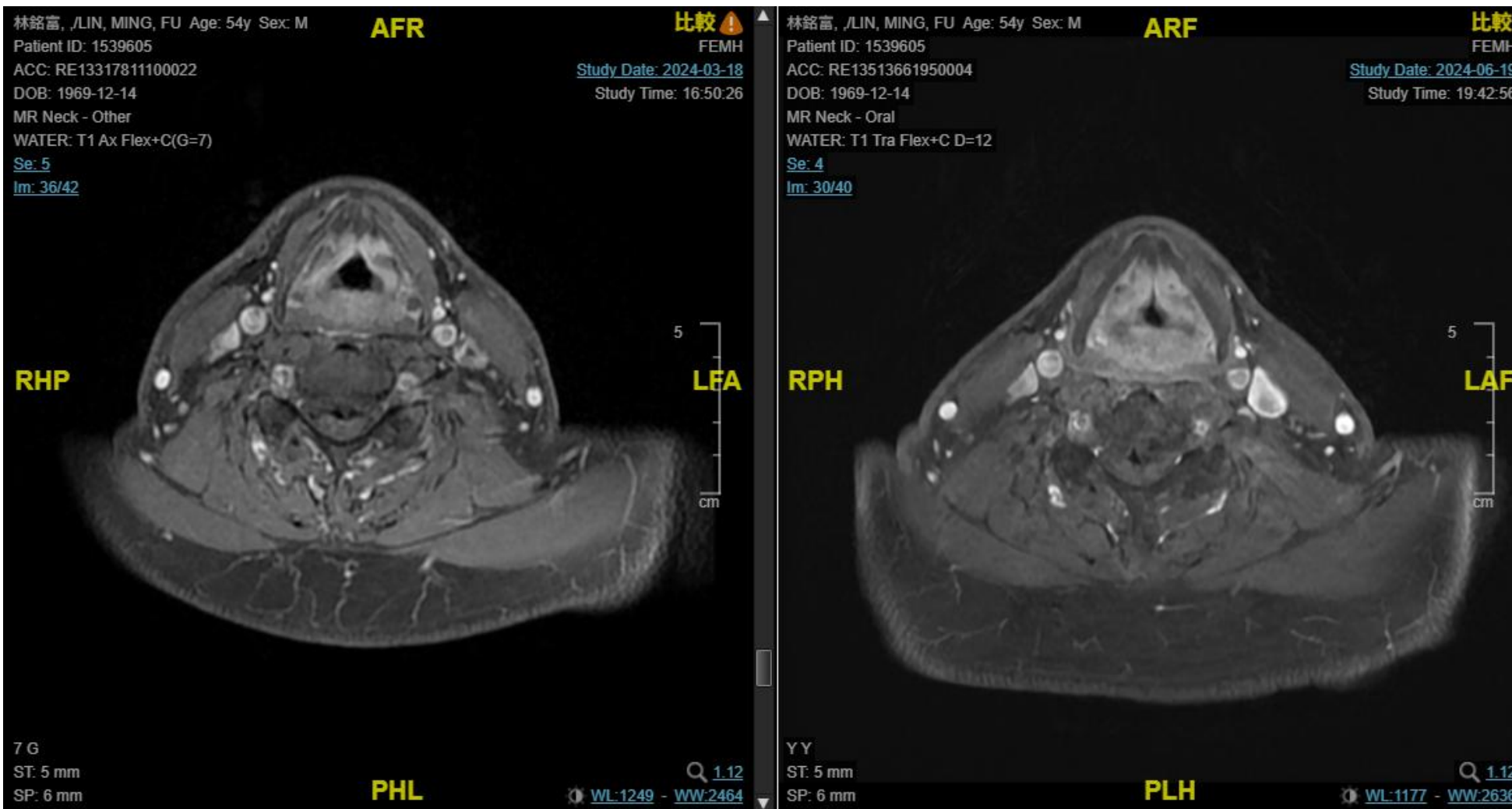


2024/04/08-05/15 Radiotherapy

- Treatment Response
Clinical Assessment: **Complete Response (CR)** noted at the end of the course. No recurrence tumor seen in the follow up nasopharyngolaryngoscopy and MRI.

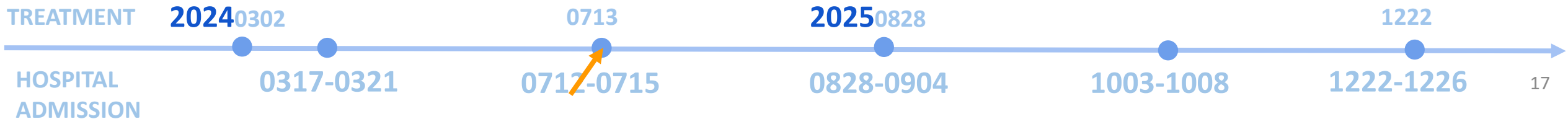
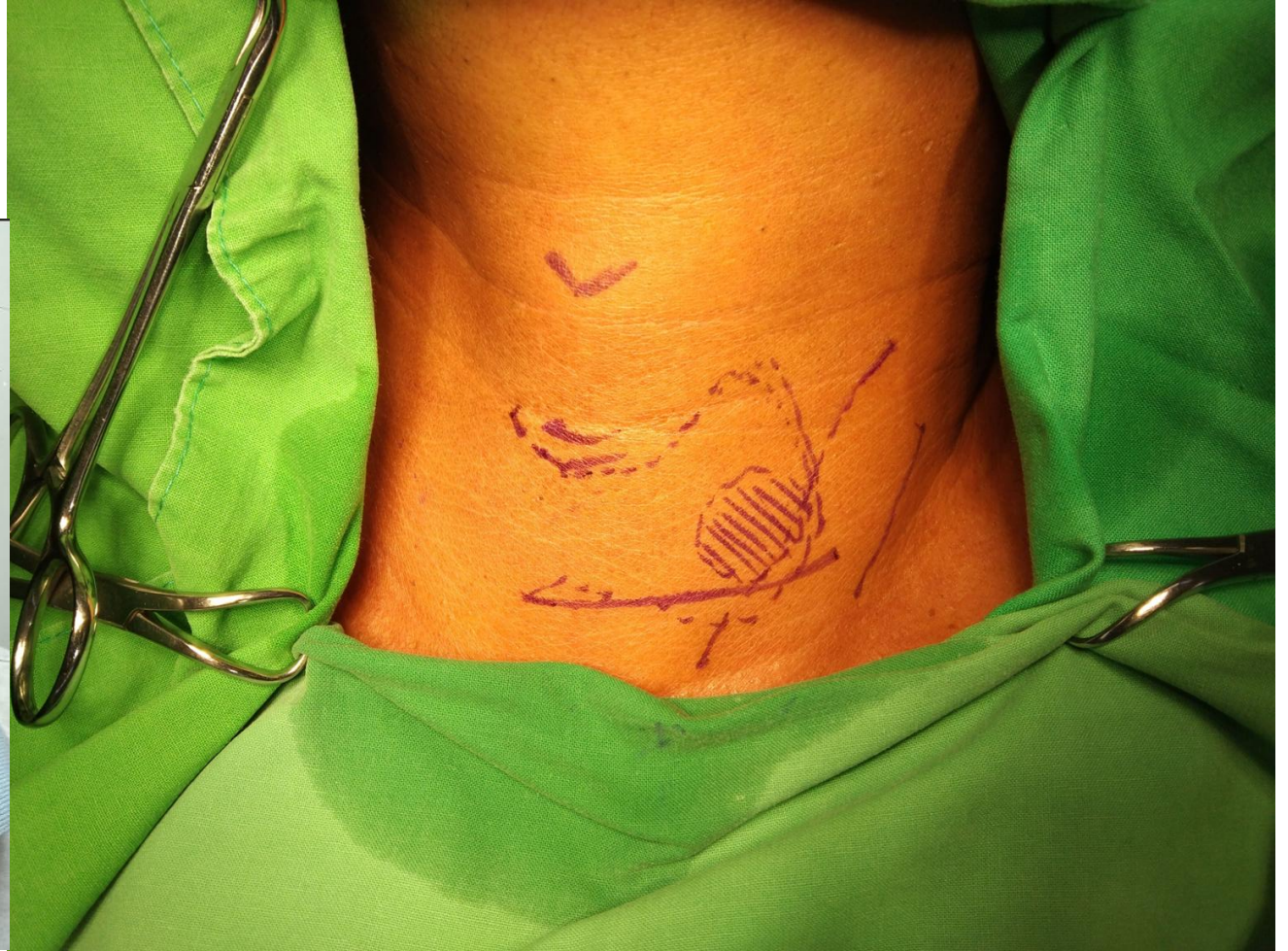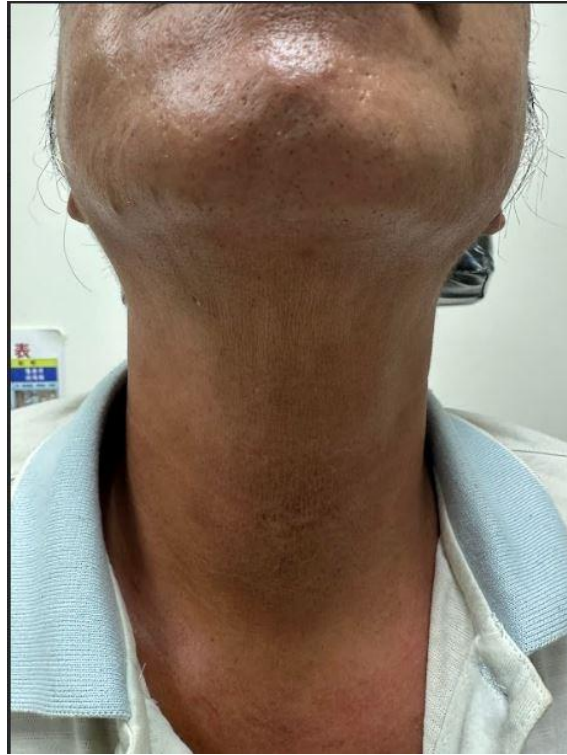


2024/04/08-05/15 Radiotherapy

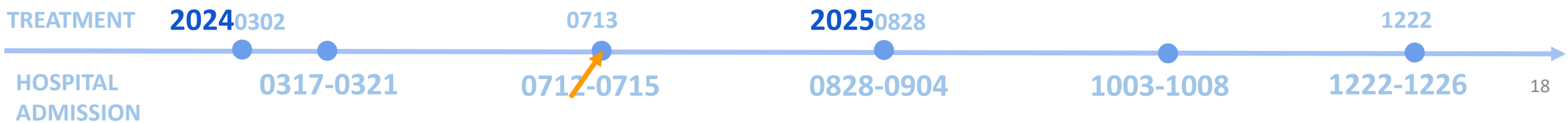
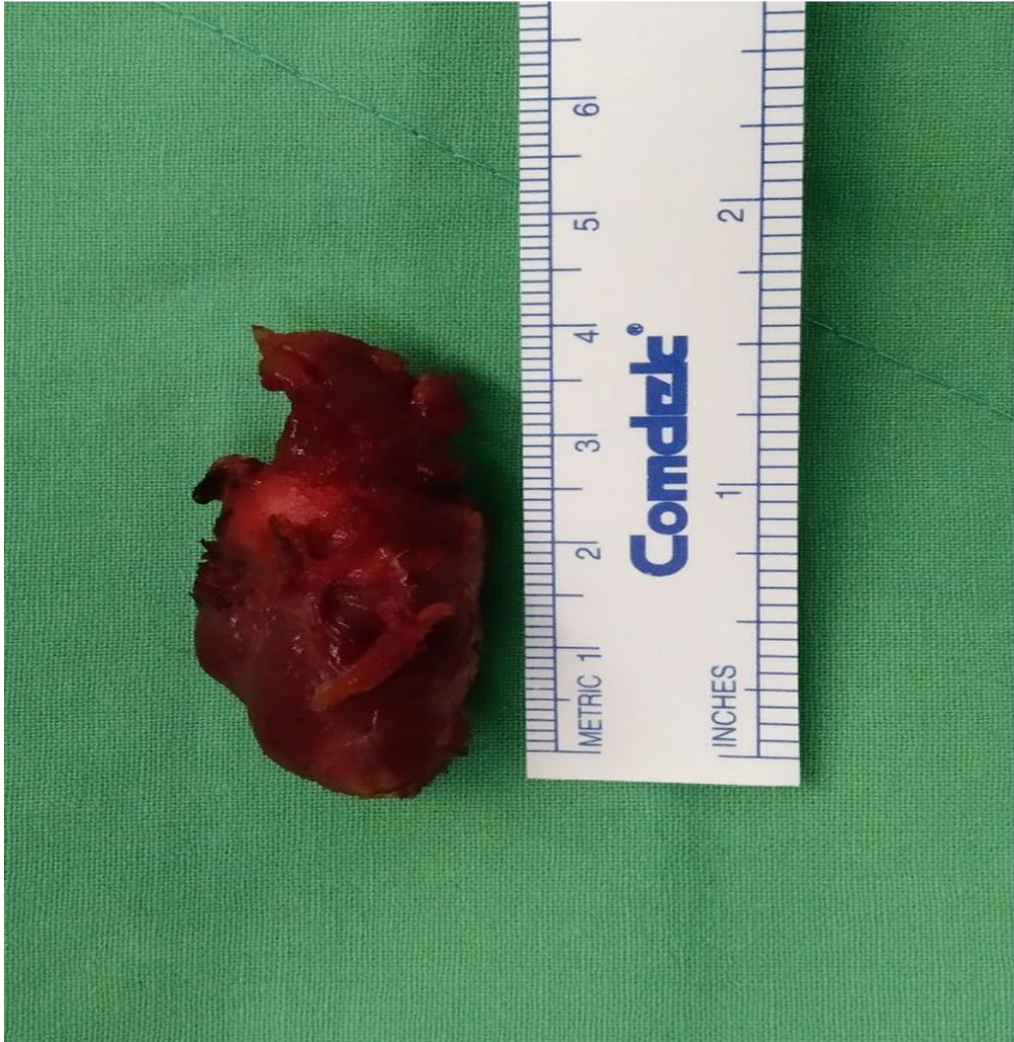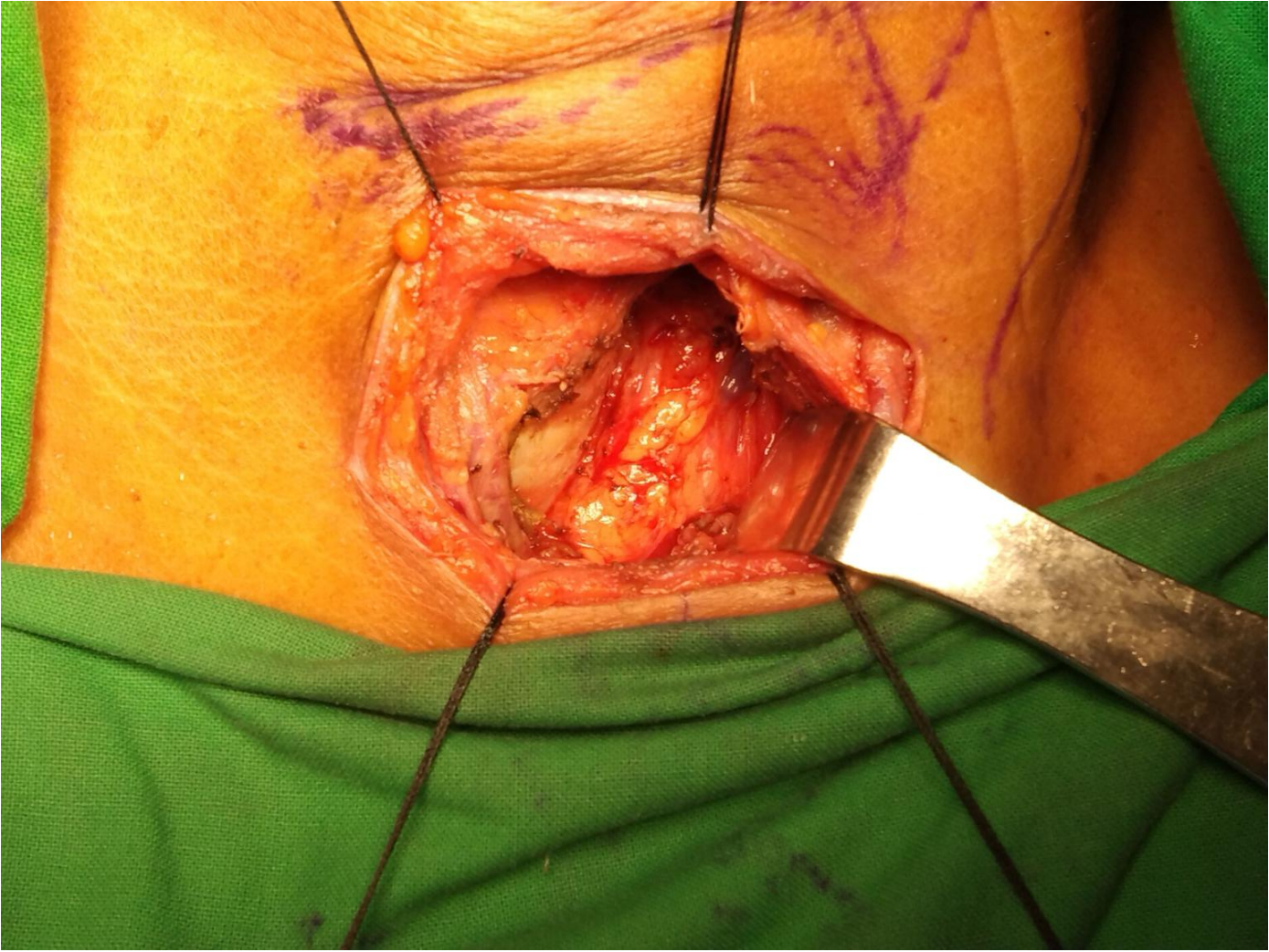


2024/07/12-15 Admitted for Surgery

- **Left Thyroid Lobectomy** with RLN monitoring.



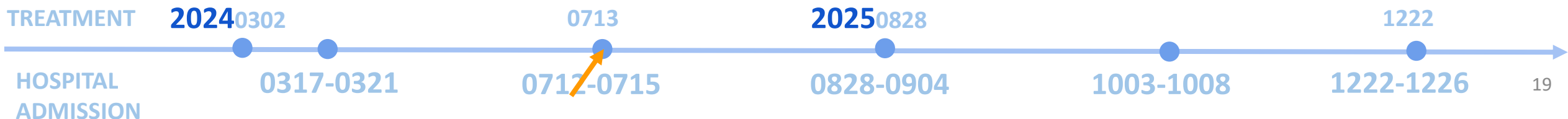
2024/07/12-15 Admitted for Thyroidectomy



2024/07/12-15 Admitted for Thyroidectomy


Pathological Findings

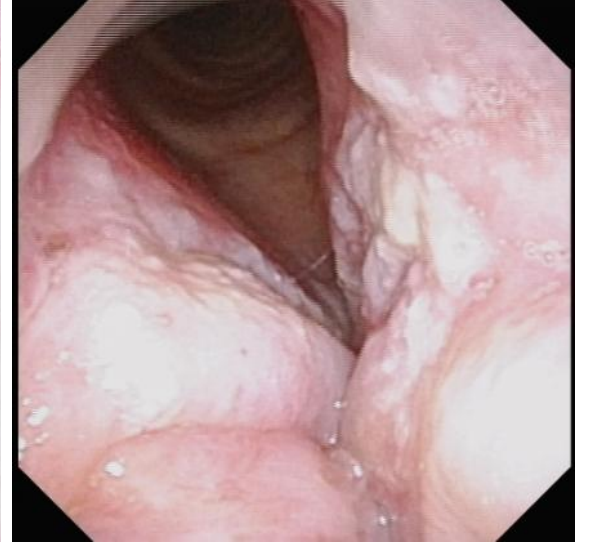
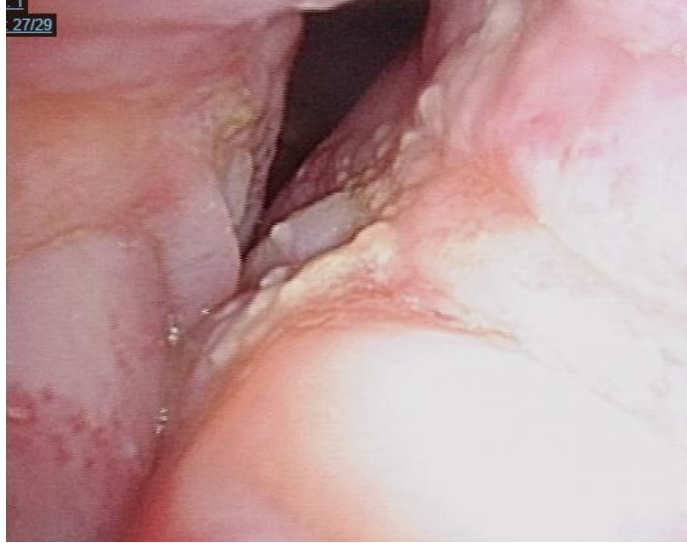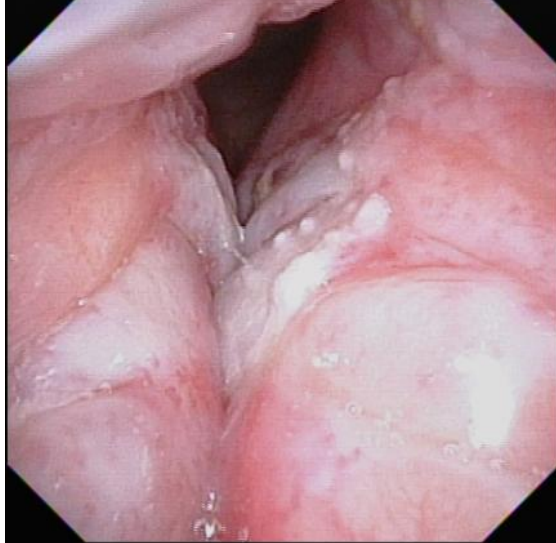
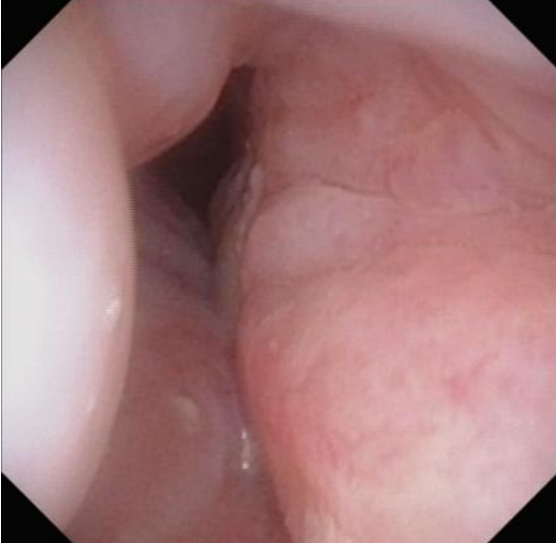
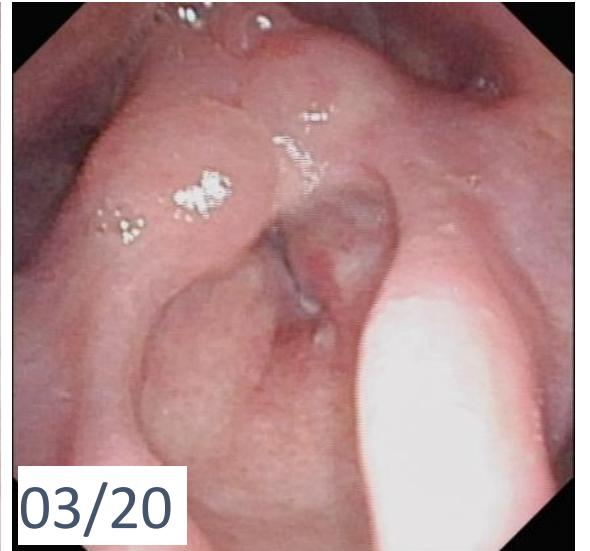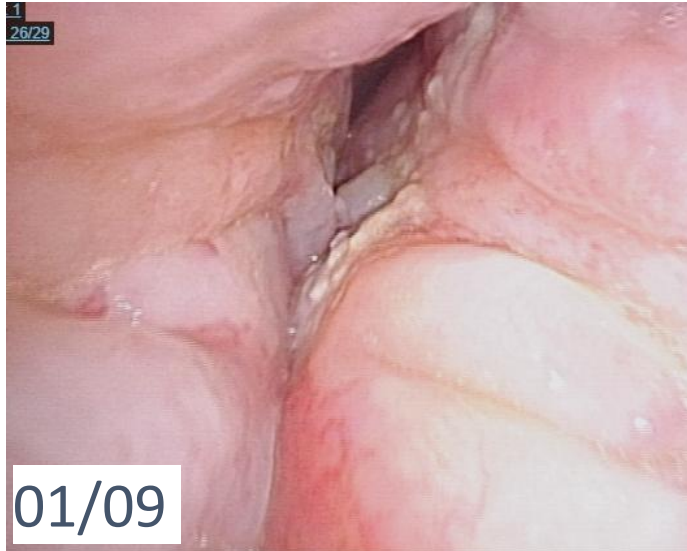
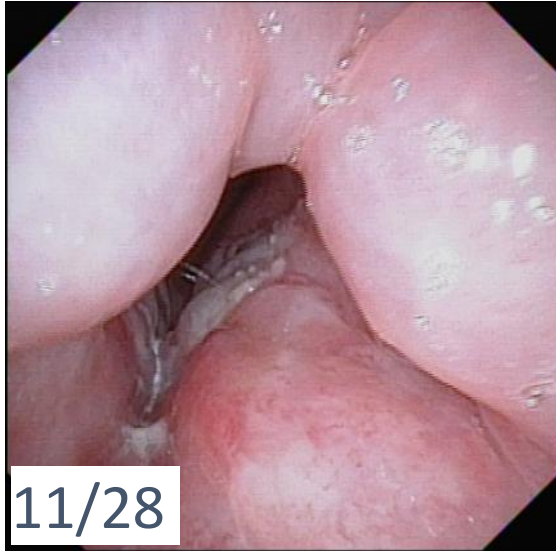
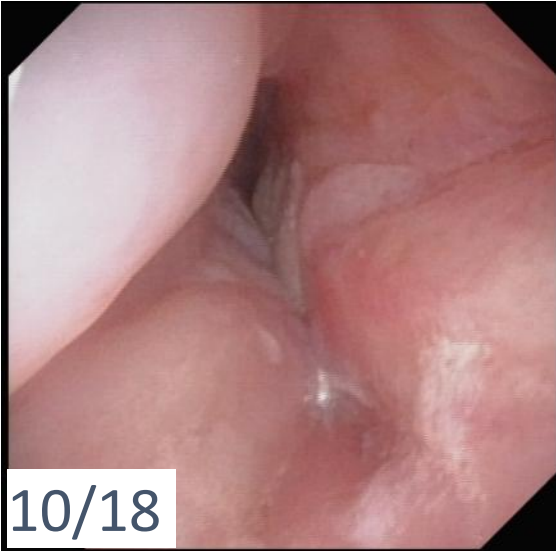- Left Thyroid Lobe
 - Diagnosis: **Papillary Carcinoma**, Classic Type.
 - Tumor Size: 1.5 x 1.3 x 1.0 cm.
 - Staging: **pT1bNx**
 - Margins uninvolved by invasive carcinoma

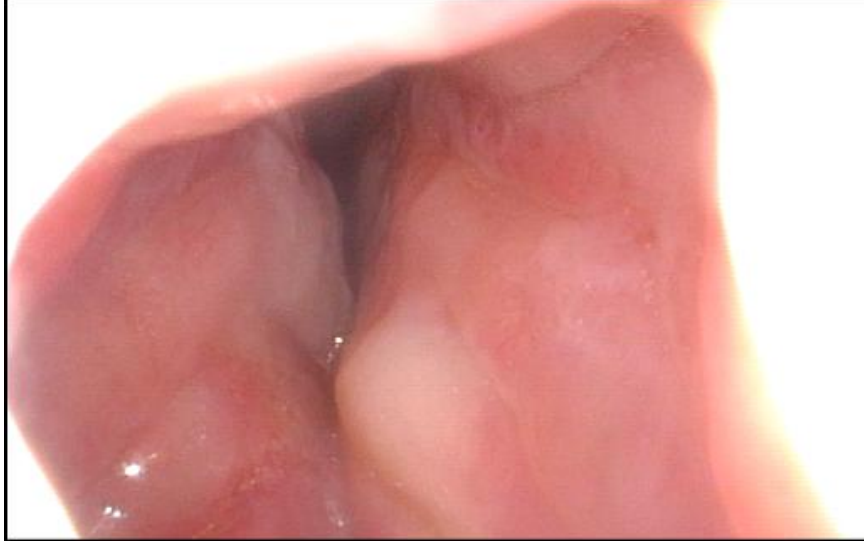
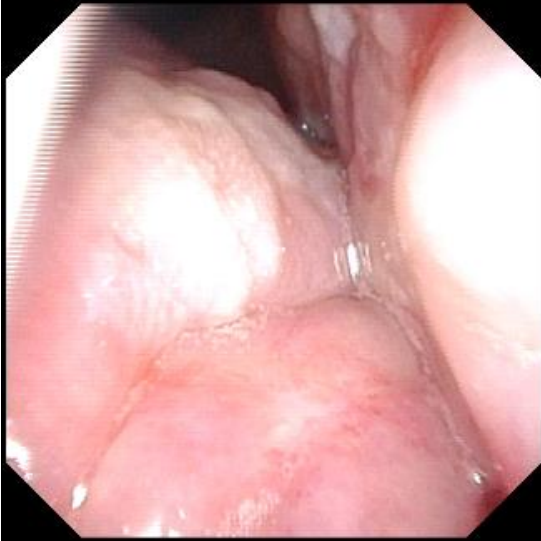
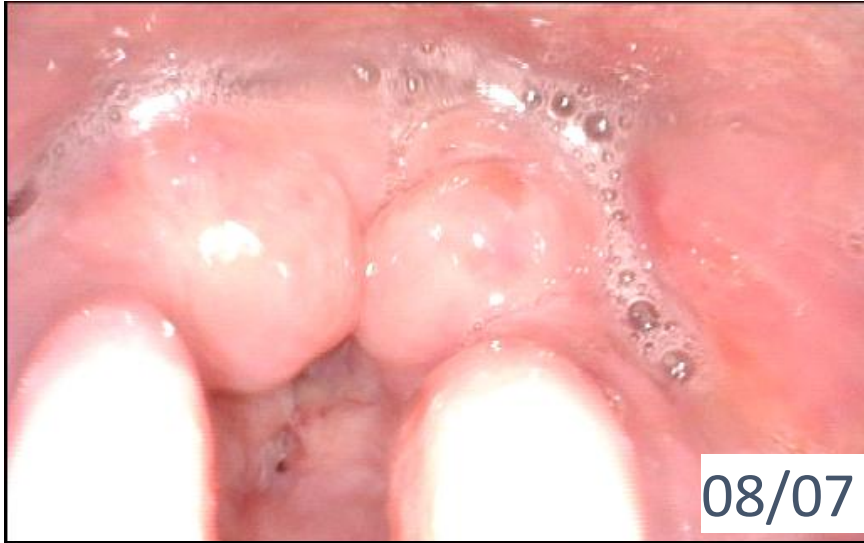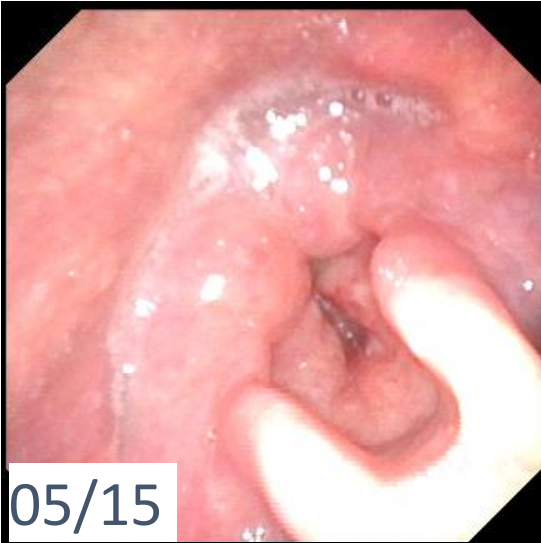Latent Period & Onset of Symptoms


- First show of **mild dysphagia** on 2024/11/28
Persistent sore throat, hoarseness, and progressive odynophagia (Pain VAS score reached 8). In late 2025, the patient reported progressive hoarseness and **exertional dyspnea**.







- **08/07:** mucopus in nasal cavity, smooth NP, laryngeal edematous change, **arytenoid swelling and injected. irregular VF surface, bulging ventricle, mild airway compromise**




Latent Period & Onset of Symptoms

Assessment:

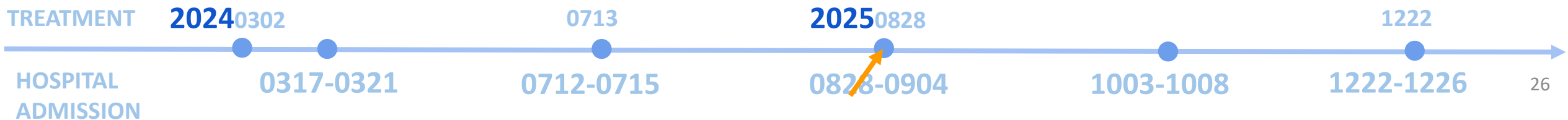
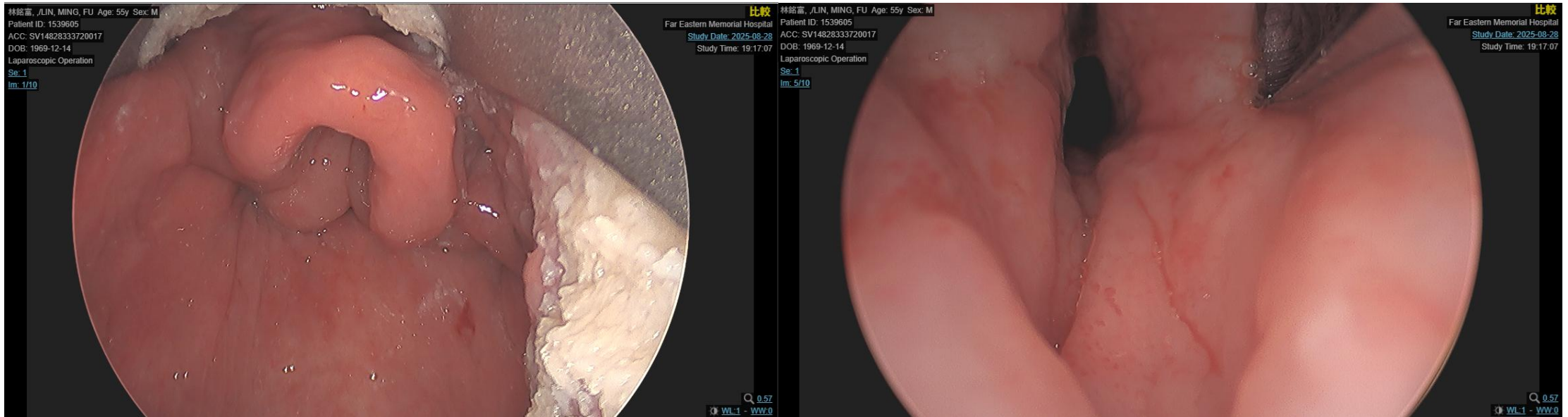
Suspected Chondroradionecrosis (CRN) or Tumor Recurrence.

Plan	<p>medication and OPD f/u (closely monitor breathing status) Go to ER if dyspnea develops (inform the risk of airway obstruction)</p> <p>I strongly suggest LMS biopsy or esophagnoscopy for bilateral VF lesion/leukoplakia and bulging ventricle site, but the patient hesitated. (closely f/u every month)</p>
-------------	---



2025/08/28 First Airway Emergency

Patient presented to the ER with worsening sore throat and hoarseness

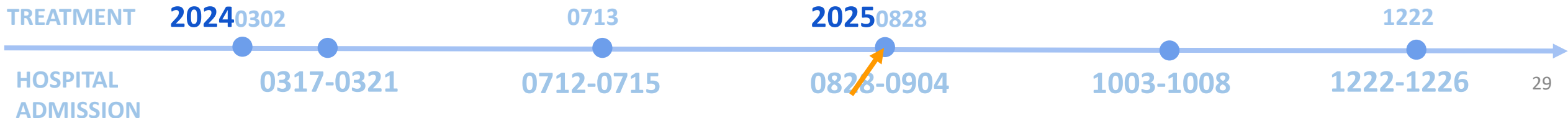


2025/08/28-09/04 Admitted for Tracheostomy

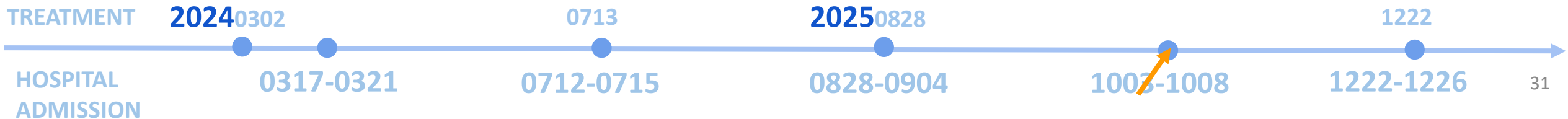
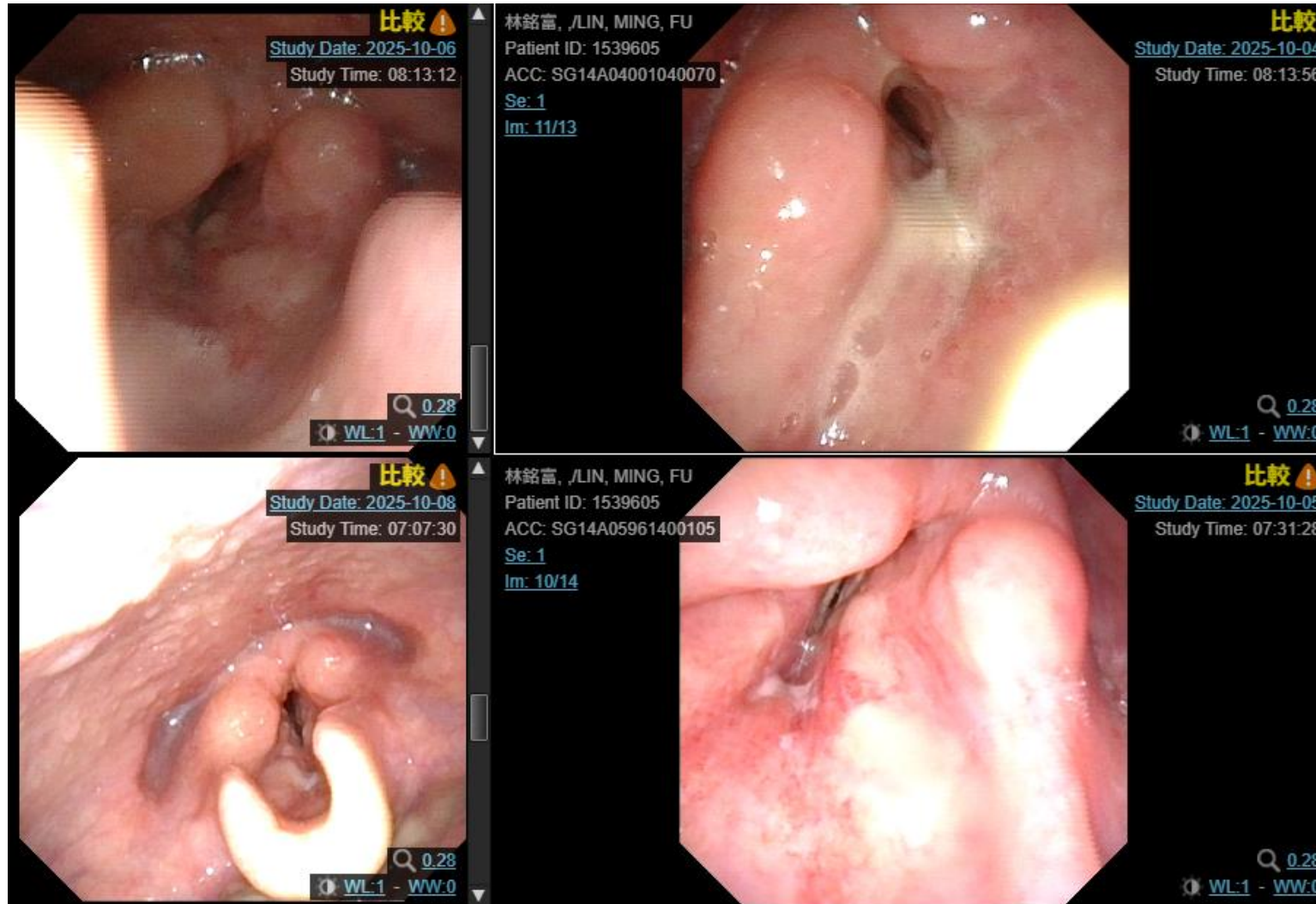
Emergent Tracheostomy performed to secure the airway.

Laryngeal Microsurgery (LMS) Biopsy: Performed concurrently to rule out cancer recurrence.

Pathology Result: Squamous Hyperplasia (No malignancy found).



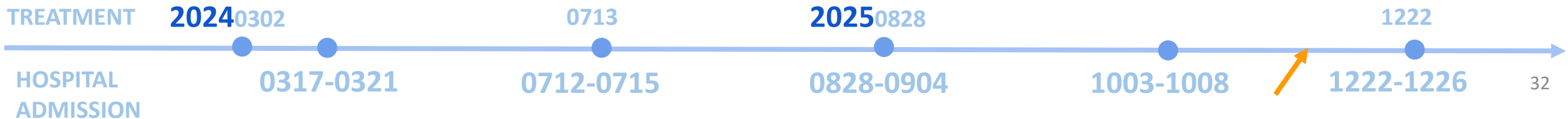
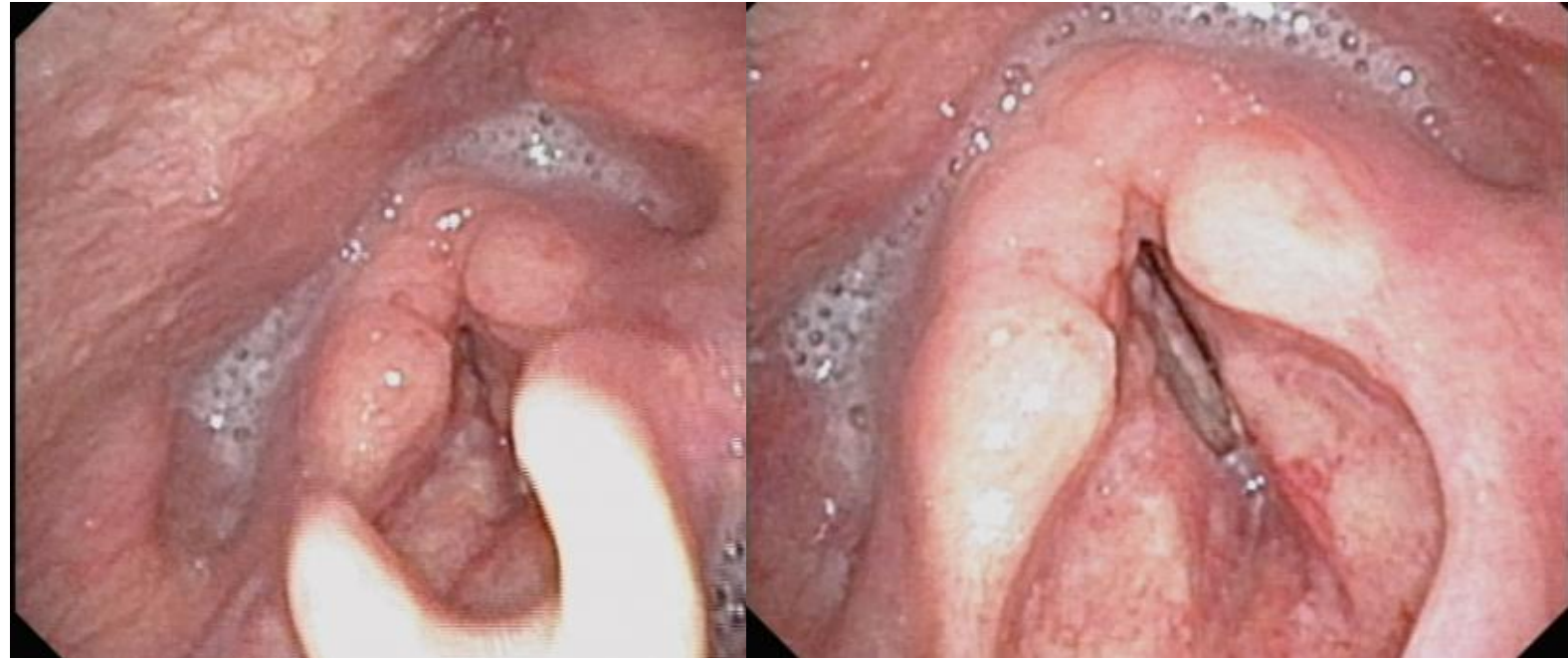2025/10/03-08 Admitted for Decannulation



Recurrence of Airway Obstruction

Nov 2025: Symptoms returned within weeks. Moderate-to-severe airway compromise noted. Patient refused re-intubation.

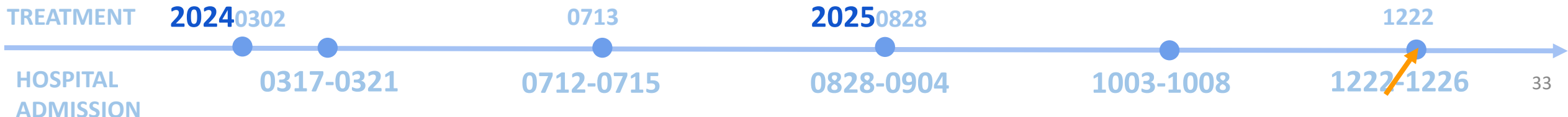
Nasopharyngolaryngoscopy:
smooth NP with mucus,
laryngeal edema, slit airway,
progressed, moderate-severe
airway compromise, **bilateral
VF stiffness and poor movement**



2025/12/22 ER

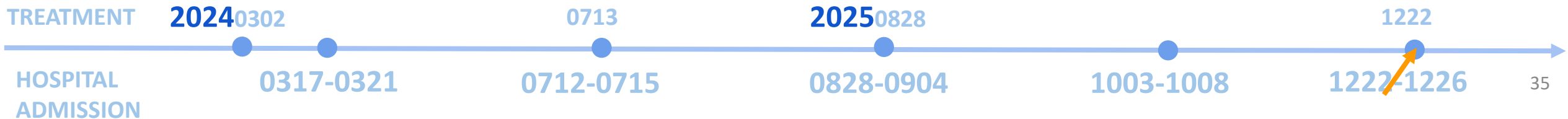
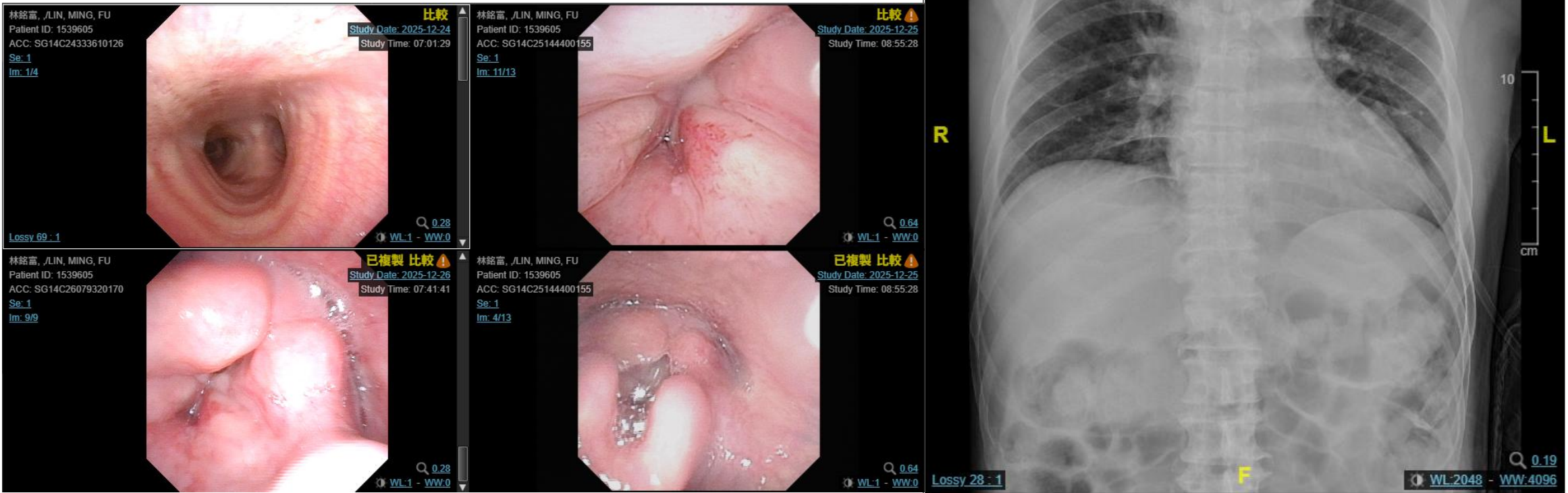
Patient returned to ER with dyspnea and stridor for 1 day

主述	progressive neck swelling and sore throat for 1+ months poor response to steroid and painkiller 12/11 fiber at ENT opd: moderate-severe airway compromise refused tracheostomy then return today due to dyspnea
客觀	Consciousness: clear Neck: stridor + Chest: strenuous pattern, bilateral clear Abdomen: no tenderness Extremities: freely movable



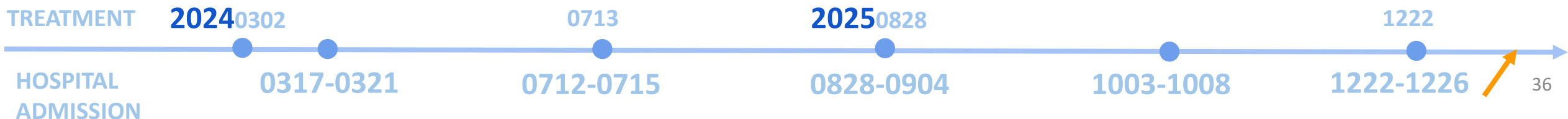
2025/12/22-26 Admitted for Re-Tracheostomy

He tolerated post-operative course well. Under stable condition, he was discharged on 2025-12-26.




Current Status

- Laryngeal Squamous Cell Carcinoma, cT1N0M0, Stage I, s/p definitive Radiotherapy (6300 cGy/28 fx) due in May 2024, CR
- Left Thyroid Papillary Thyroid Carcinoma, pT1bNx, s/p left thyroid lobectomy.
- Post-RT Bilateral Vocal Fold Palsy, s/p Tracheostomy



Discussion



Volume 170, Issue 3

March 2024

Pages 724-735

Impact factor: (2024): 2.5

Management of Bilateral Vocal Fold Paralysis: A Systematic Review

Otolaryngology – Head and Neck Surgery, March 2024 Page 724-735 (Impact Factor in 2024: 2.5)

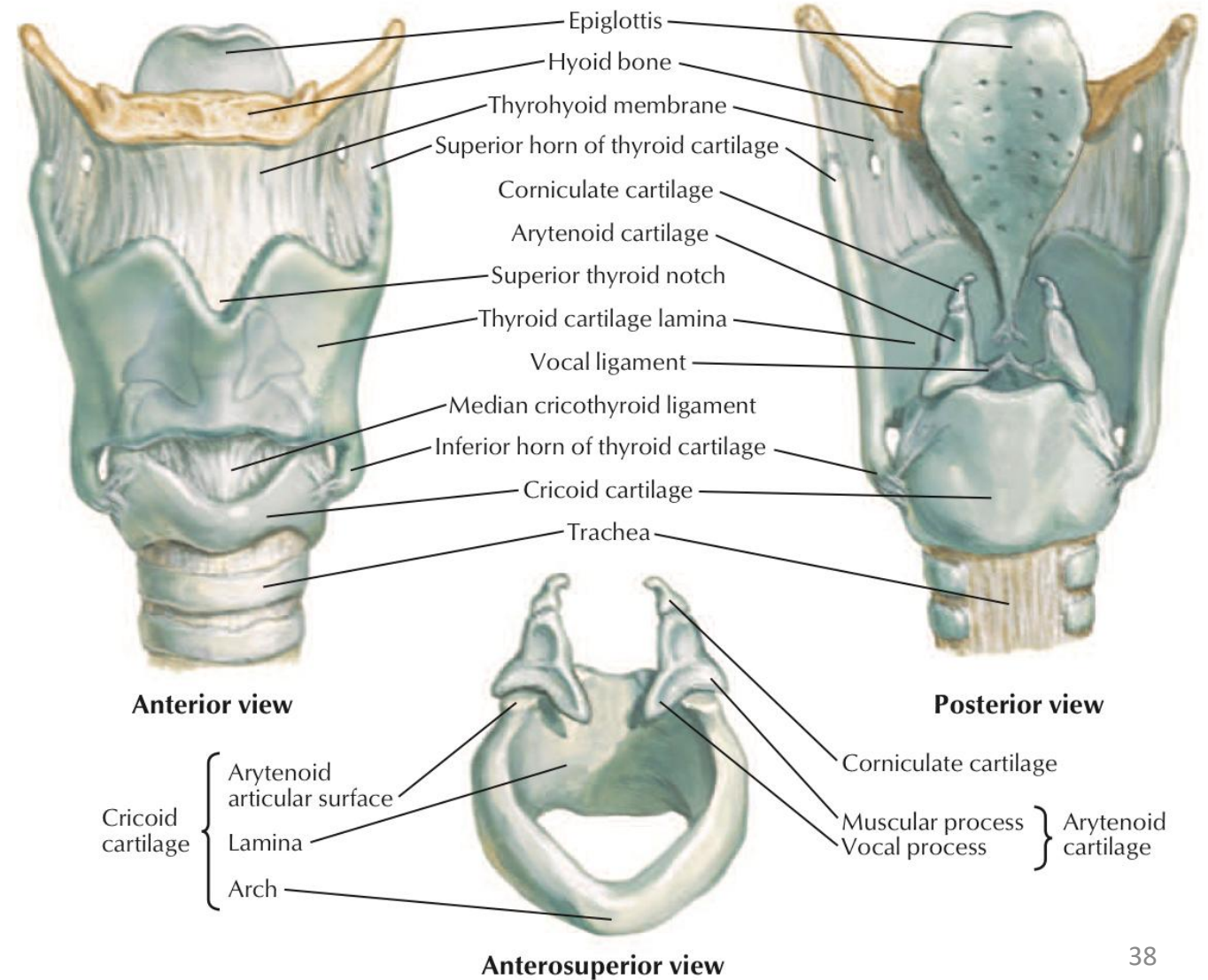
Jérôme R. Lechien MD, PhD, MS, Stéphane Hans MD, PhD, MS, Ted Mau MD, PhD

Department of Otolaryngology, Elsan Hospital, Paris, France.

Department of Otolaryngology-Head & Neck Surgery, Foch Hospital, School of Medicine, UFR Simone Veil, Université Versailles Saint-Quentin-en-Yvelines (Paris Saclay University), Paris, France.

Background of this study

- Larynx anatomy review



Background of this study

- Larynx anatomy review – intrinsic muscles of the larynx

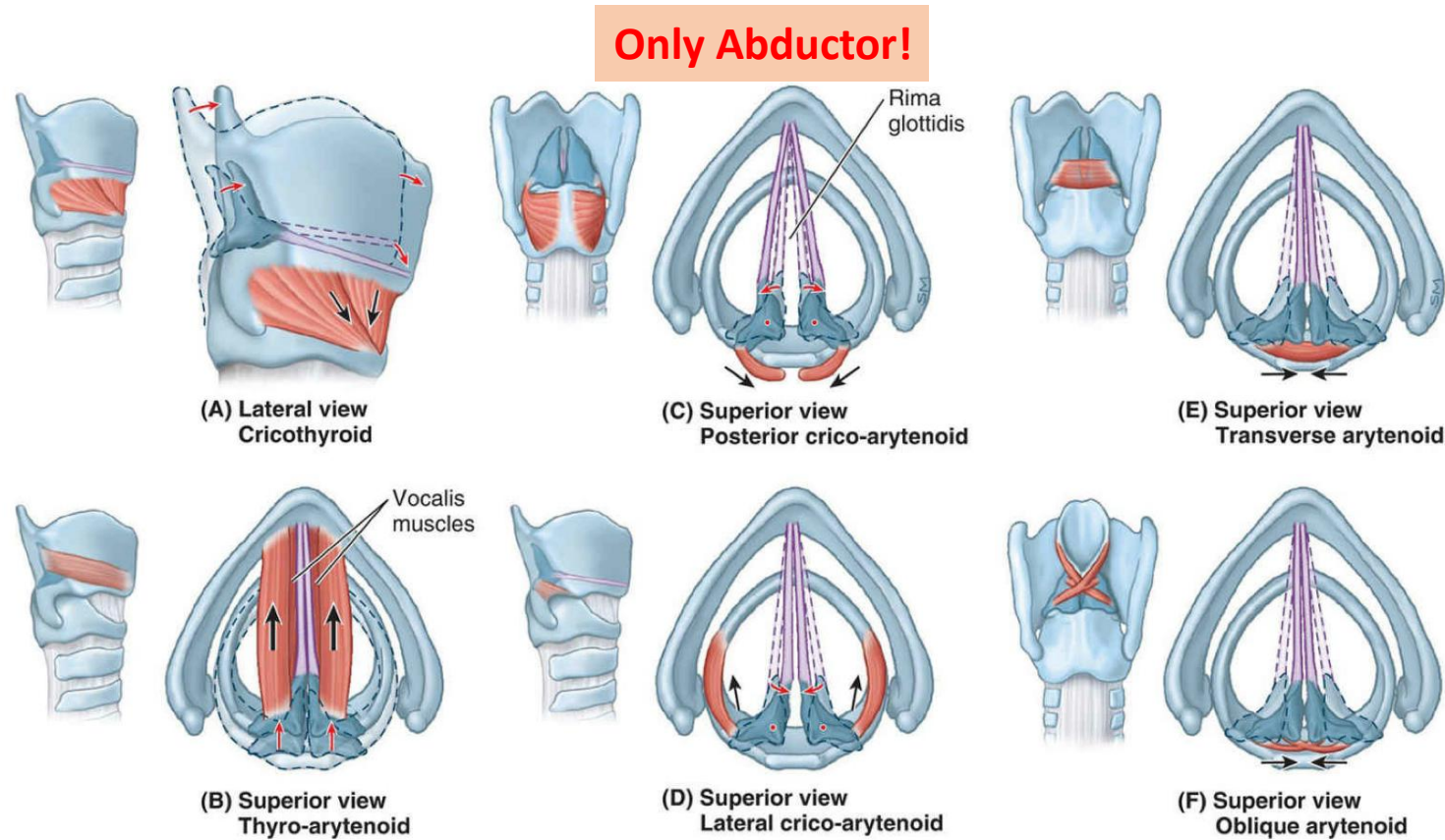
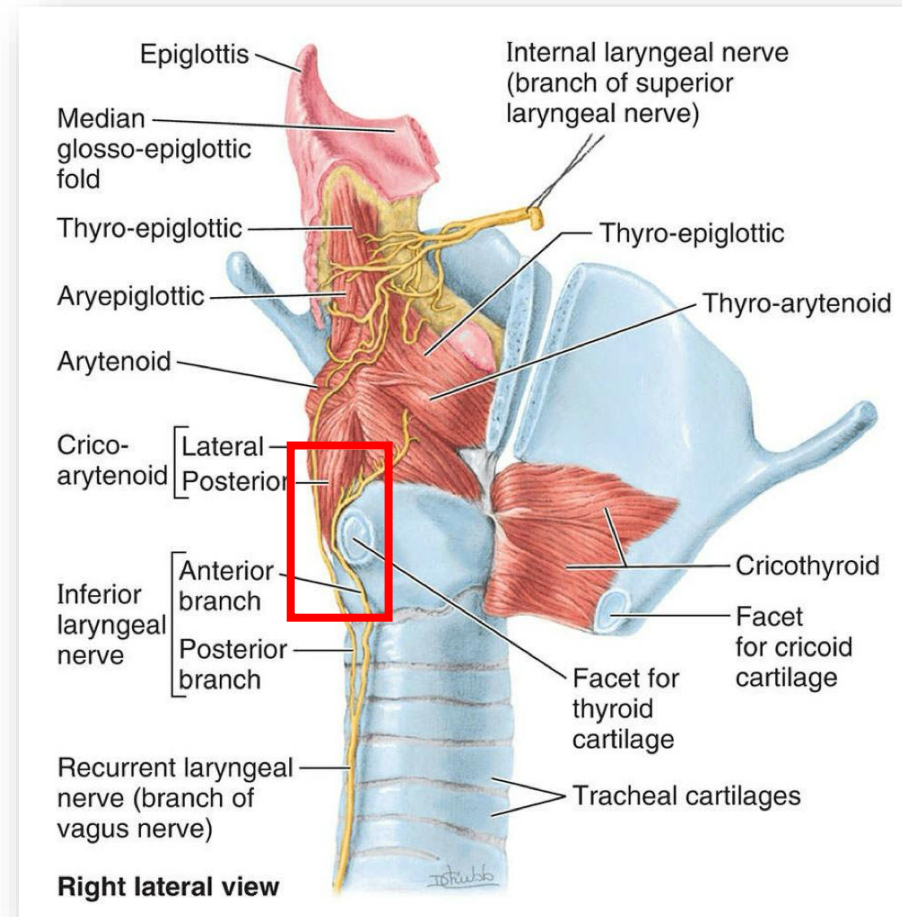
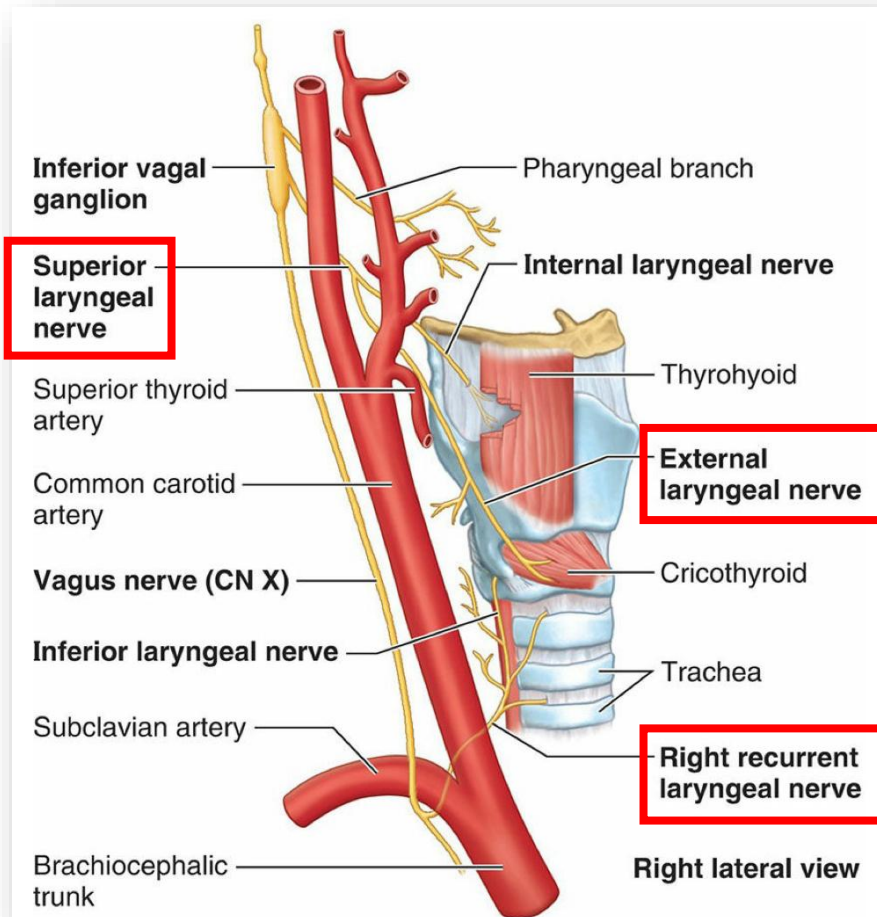


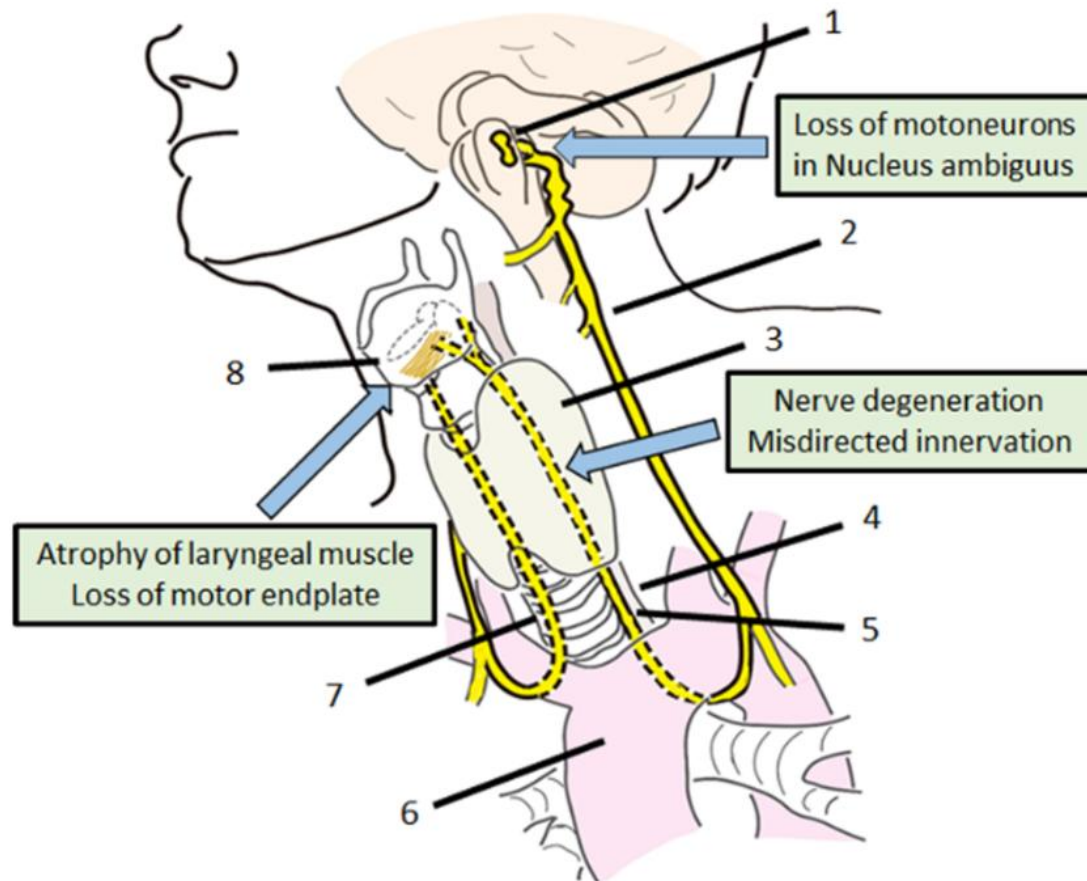
FIGURE 9.39. Muscles of larynx.

Background of this study

- Larynx anatomy review – innervation of intrinsic muscles



Background of this study

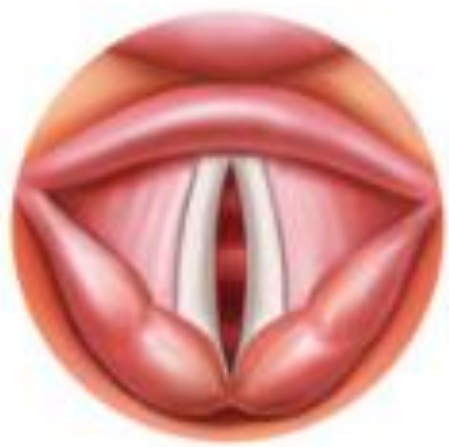
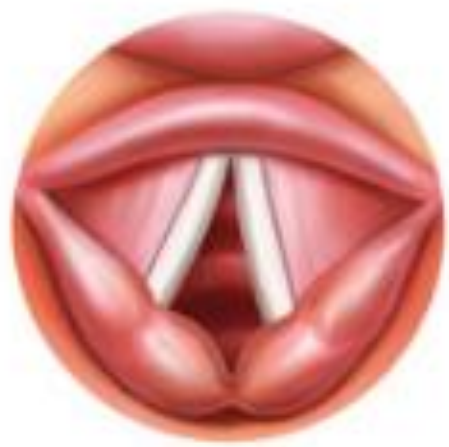
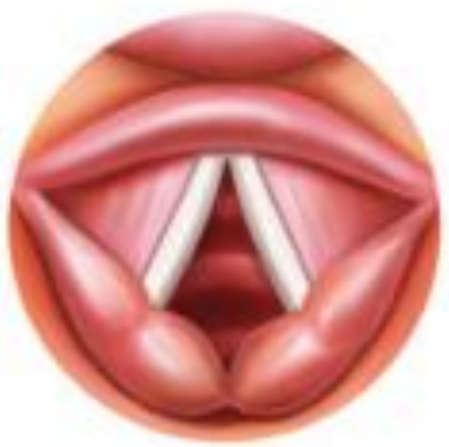- **Bilateral vocal fold paralysis (BVFP)** is a neurological condition associated with **reduced or absent movement of both vocal folds**
- processes affecting the **neurological control of vocal fold movement**
 - Central neurologic problems
 - Neuropathies of the vagus nerve or the recurrent laryngeal nerve (RLN)
 - Neuromyopathies

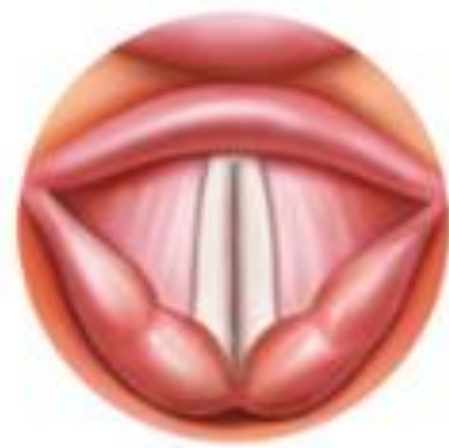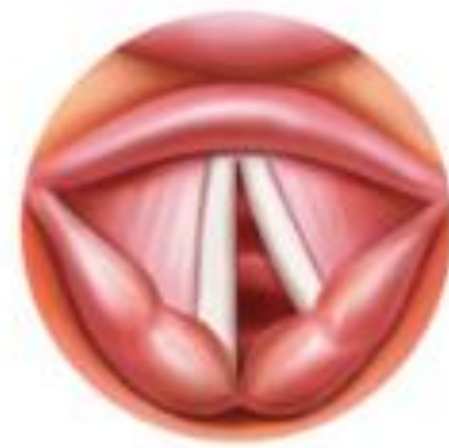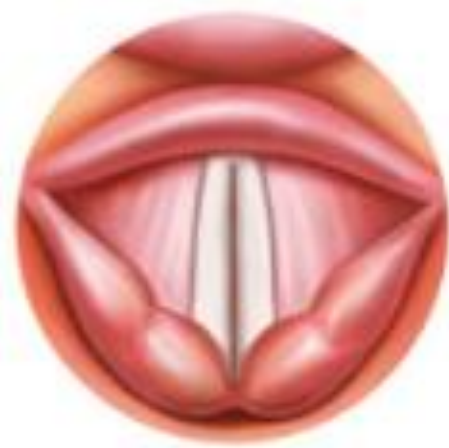Vocal cord paralyses

Background

• C Respiration



• S Phonation



w/o paralysis

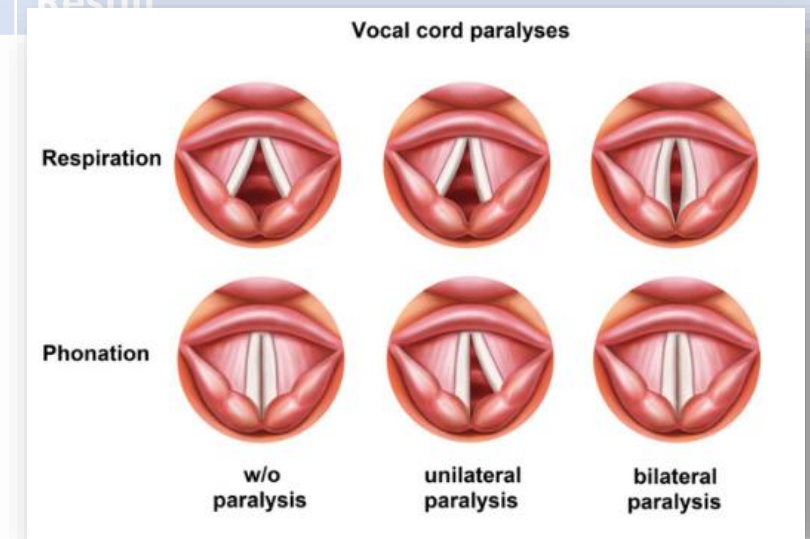
unilateral paralysis

bilateral paralysis

Primary

Background of this study

- **Clinical manifestation** of vocal cord paralysis
 - depends on the
 - (1) **Functional impairments** (paralysis vs paresis)
 - (2) **Position** of paralyzed vocal folds (usually **paramedian**)
 - **Inspiratory dyspnea and noisy breathing**
 - **Dysphonia**
- Sometimes needs urgent or long-term intervention




Primary objective of surgery: to relieve the dyspnea while maintaining the voice quality as much as possible

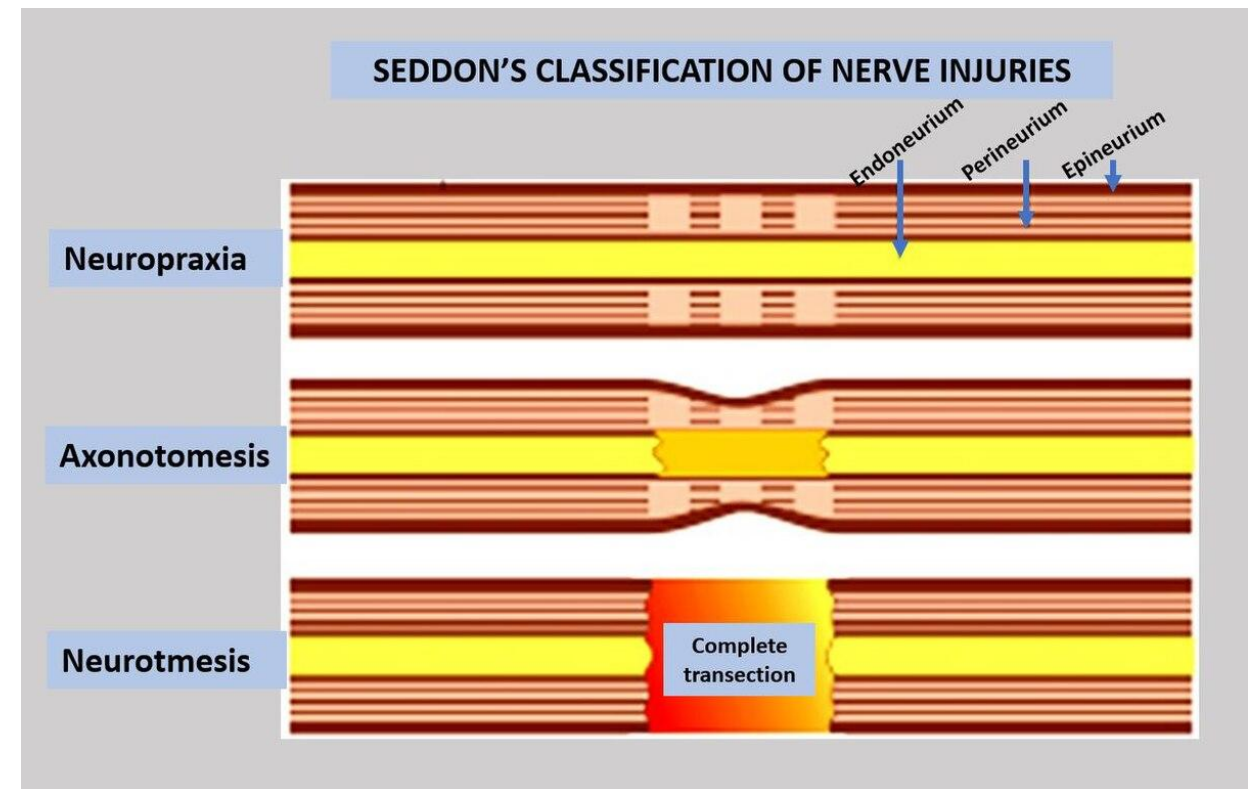
Background of this study

- Pathophysiology of vocal cord paralysis

- **Stretching**
- **Crushing**
- **Thermal injury**
- **Electrical injury**
- **Transection**

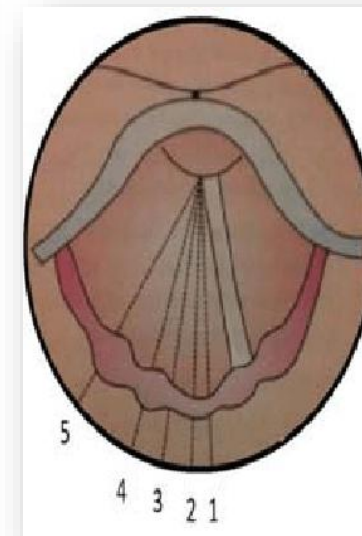
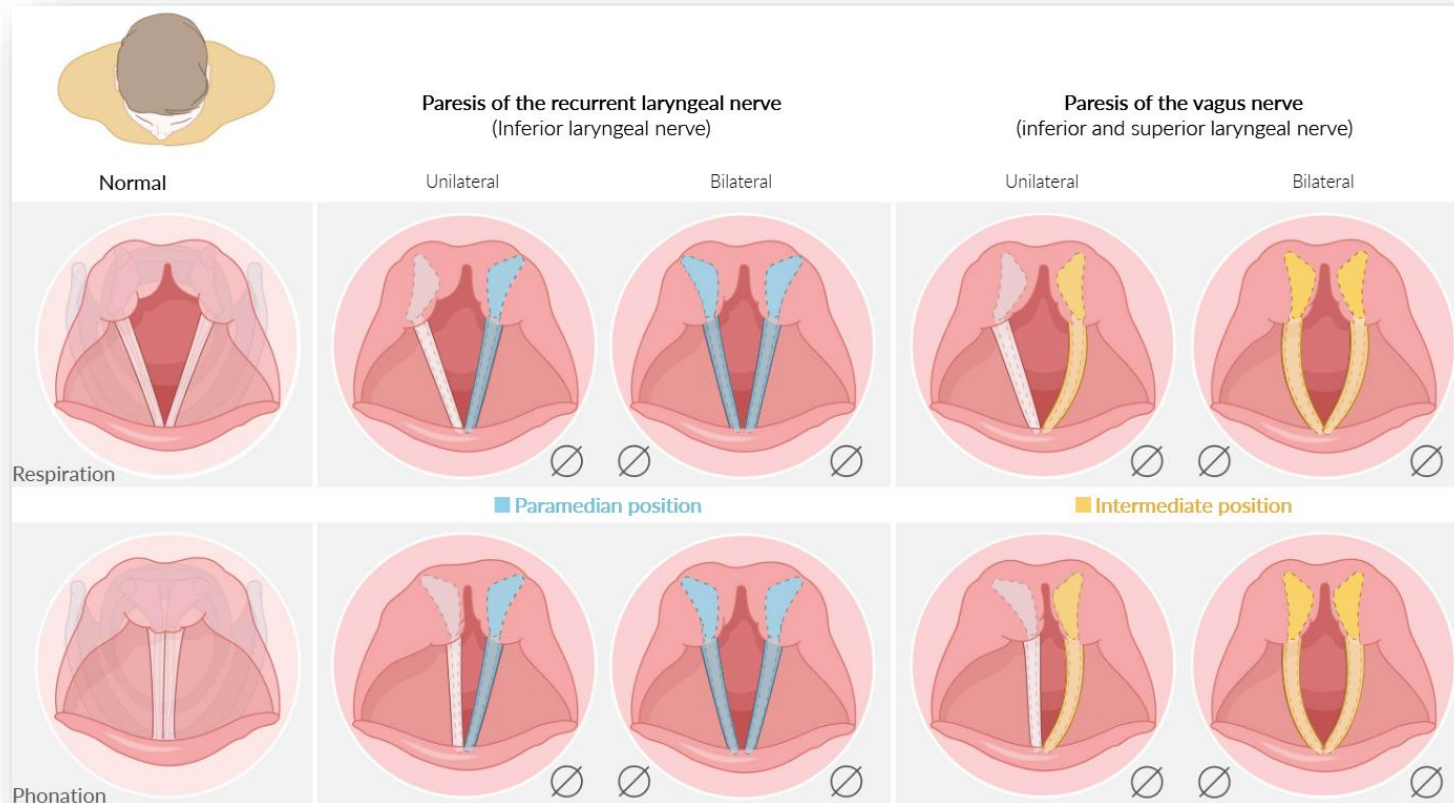


Recurrent Laryngeal Nerve



Background of this study

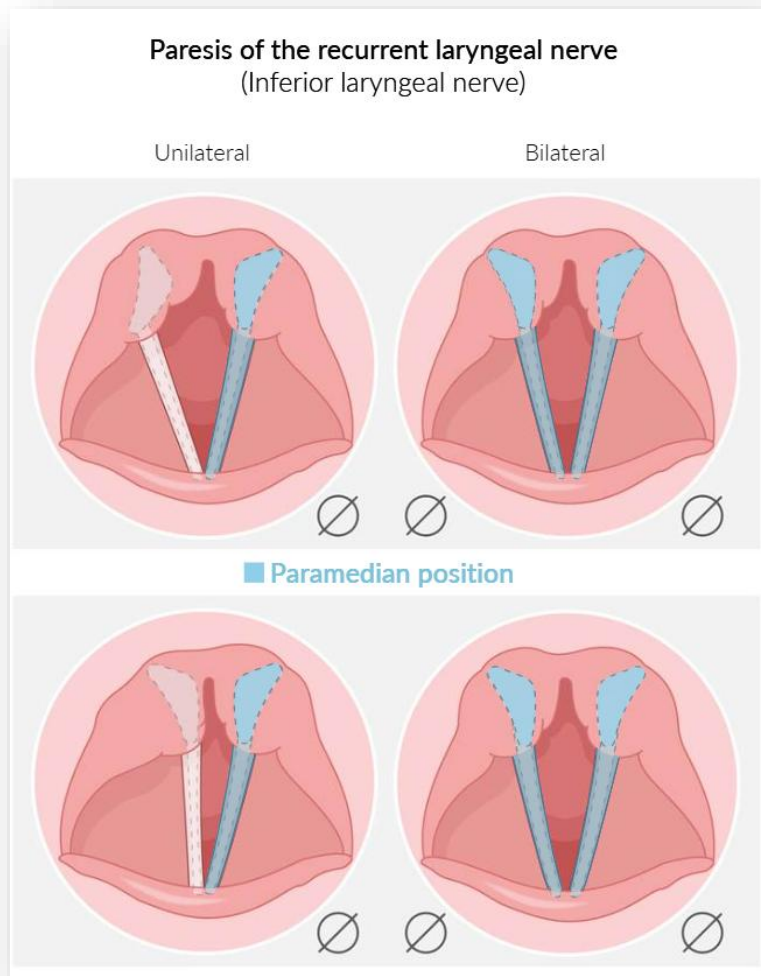
- **Paramedian position**



Vocal fold position	Distance from the midline
1. Median	0 mm
2. Paramedian	1.5 mm
3. Intermediate	3.5 mm
4. Partial abduction	7 mm
5. Total abduction	9.5 mm

<https://next.amboss.com/us/article/T6064S>

Background of this study



- **Wagner-Grossmann theory**

- vocal cord remains in the paramedian position because of **adduction from the intact cricothyroid**
- lack of correlation between glottic configuration and EMG activity of the cricothyroid -> **refuted**

- **Passive biomechanical / joint constraint theory**

- **Also, selective vulnerability & synkinesis**
 - inconsistency in axonal regrowth
 - inappropriate reinnervation of abductor and adductor muscles

Aim of this study

to review the current literature about the

(1) Epidemiology

(2) Etiology

and (3) Surgical management

of BVFP in the adult population

Method

- **Databases: PubMed, Scopus, and the Cochrane Library**
- **Keywords include:**
 - "vocal cord," "vocal cord paralysis/epidemiology," "vocal cord paralysis/etiology," "vocal cord paralysis/surgery," "bilateral," "management," and "procedure"
- **Review Protocol:** The review followed the **PRISMA**

✓ Inclusion Criteria:

- **Study Types:** Peer-reviewed prospective/retrospective studies, reviews, and meta-analyses
- **Population:** Adults
- **Diagnosis:** Must be supported by clinical history, endoscopy, or electromyography (EMG)

✗ Key Exclusion Criteria:

- **Format:** Case reports
- **Population :** Pediatric populations
- **Diagnosis Issues:** Unspecified laryngeal immobility or posterior glottic stenosis
- **Methods:** Combined surgical approaches

Method

- **Outcomes Analyzed:**

- Researchers reviewed study design, patient demographics, etiologies, baseline tracheotomy rates, specific surgical procedures, **decannulation rates, functional outcomes (voice, swallowing, airway), complications, and revision rates**

- **Statistical Approach:**

- Due to **significant heterogeneity** among studies regarding decannulation and functional outcomes, a **qualitative summary** was conducted rather than a formal meta-analysis.

Result

- **Reversible treatments** for acute airway distress
 - tracheotomy and laterofixation of the vocal folds
- **Botulinum toxin injections**
- **Permanent surgery (discuss further later)**
- Among **55 article** were reviewed:
 - Laterofixation of the vocal folds: 9
 - Unilateral posterior transverse cordotomy: 9
 - Bilateral posterior transverse cordotomy: 7
 - Unilateral/bilateral partial arytenoidectomy: 4
 - Total arytenoidectomy : 6

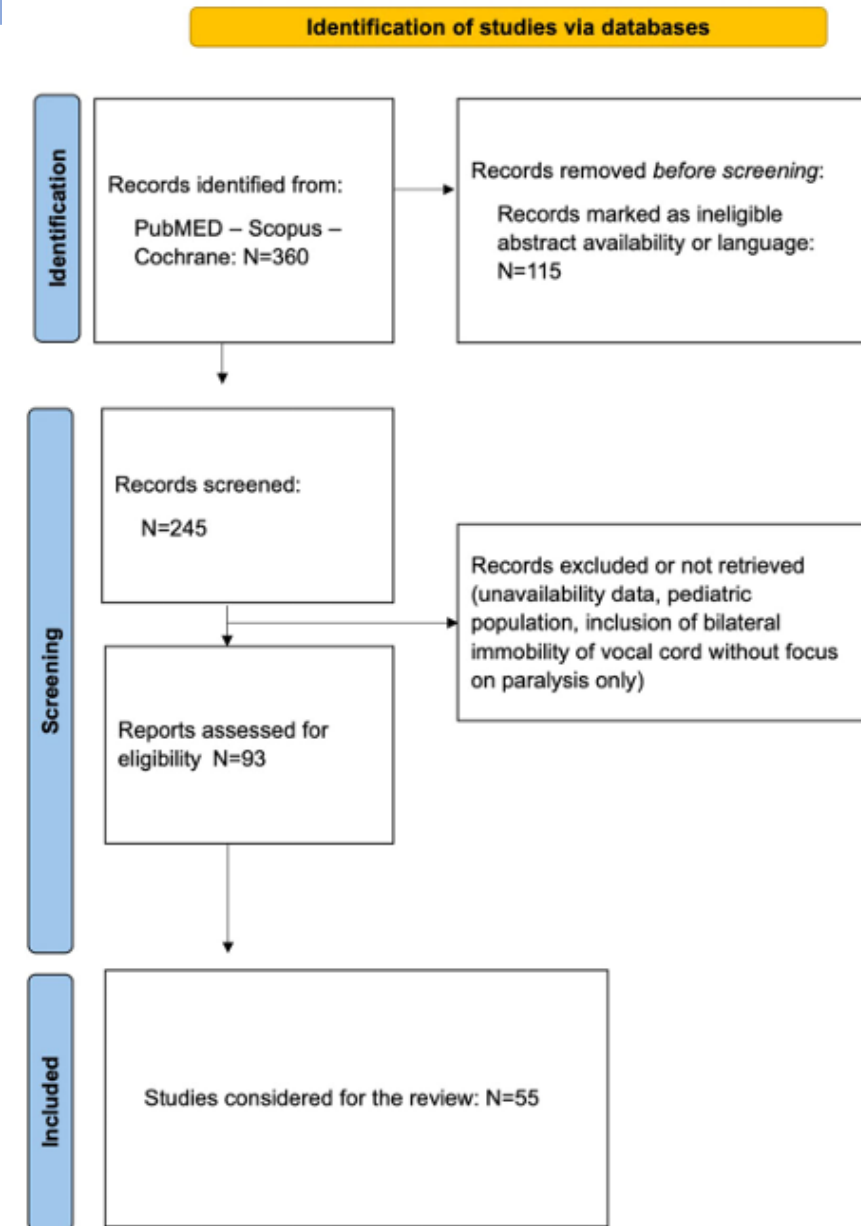


Figure 1. Preferred reporting items for systematic reviews and meta-analyses flow chart.

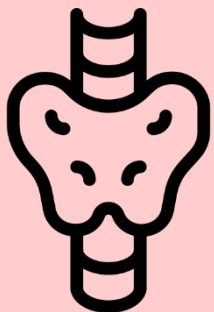Result – Epidemiology

- **Prevalence and Incidence:** Currently **uninvestigated** in the general adult population

incidence

0.2-0.6%

in thyroidectomy cases



28%

requiring surgical
management



Median diagnostic time

6.7 m.

postoperatively



annual reduction

↓ **9%**

over the past 2 decades



Result – Epidemiology

Table 5. Multivariate Analysis: Characteristics Independently Associated with Vocal Fold Paralysis.

Characteristic	Odds ratio (95% confidence interval)	P value
Age	1.03 (1.01-1.04)	.001
Race		
Caucasian	Reference	
Non-Caucasian	1.41 (1.12-1.78)	.004
Stage		
Localized	Reference	
Regional	3.31 (2.67-4.10)	<.001
Regional with lymph node involvement	5.80 (4.39-7.66)	<.001
Histologic type		
Follicular	Reference	
Papillary	1.35 (1.03-1.77)	.029
Medullary	1.88 (1.15-3.09)	.012
Region		
Southern	Reference	
Western	1.29 (1.07-1.57)	.009
Southwestern	1.68 (1.19-2.39)	.003

Table 7. Multivariate Analysis: Characteristics Independently Associated with Bilateral Vocal Fold Paralysis.

Characteristic	Odds ratio (95% confidence interval)	P value
Stage		
Localized	Reference	
Regional	3.80 (2.10-6.92)	<.001
Regional with lymph node involvement	7.46 (3.73-14.9)	<.001
Histologic type		
Follicular	Reference	
Medullary	2.50 (1.06-5.89)	.037

Francis DO, Pearce EC, Ni S, Garrett CG, Penson DF. Epidemiology of vocal fold paralysis after total thyroidectomy for well-differentiated thyroid cancer in a Medical population. Otolaryngol Head Neck Surg. 2014 Apr;150(4):548-57. 52

Result – Etiology

- **Radiation and prolonged intubation** were suggested as potential etiologies of BVFP
- But authors included patients with **bilateral vocal fold immobility**, which may include **posterior glottic stenoses**
 - >> **Excluded during screening**

Table 1. Etiology of Bilateral Vocal Cord Paralysis

Etiology	N (1182)	Percentage
1 st Postsurgery	905	76.6
☹️ Thyroidectomy	879	97.1
Esophagectomy	13	1.4
Brain/skull base surgery	6	0.7
Tracheal/chest surgery	5	0.6
Bilateral glomus surgery	1	0.1
Thymic surgery	1	0.1
2 nd Idiopathic	82	6.9
3 rd Trauma	36	3.0
4 th Neurological diseases	29	2.5
Unspecified	19	65.5
Neuromyopathies	2	6.9
Stroke	2	6.9
Guillain-Barré	2	6.9
Neurofibromatosis	1	3.4
Brain metastases	1	3.4
Parkinson	1	3.4
Bulbar disease	1	3.4
5 th Cancers	19	1.6
Primary thyroid cancer	13	68.4
Laryngeal cancer	3	15.7
Lung cancer	1	5.3
Esophageal cancer	1	5.3
Neck metastasis	1	5.3
6 th Congenital	14	1.2
Viral	4	0.3
Strangulation	4	0.3
Tuberculosis	2	0.2
Granulomatosis with polyangitis	1	0.1

Abbreviation: N = number.

Result – Treatment Modalities

- **Reversible treatment**
 - Tracheotomy
 - Laterofixation
- **Permanent surgery**
 - Posterior Transverse Cordotomy
 - Arytenoidectomy
 - Laryngeal Reinnervation
- **Botulinum Toxin Injection**
- **Others**
 - Laryngeal pacing/ Neuromodulation/ Gene therapy/ Stem cell therapy

Reversible treatment – Tracheotomy

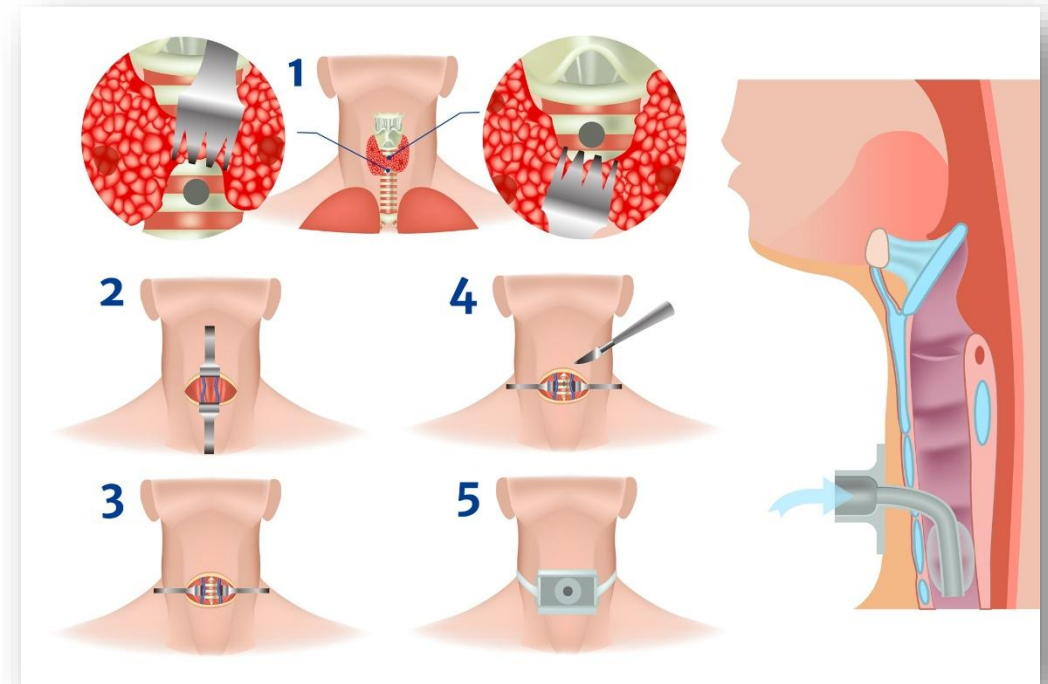
From a medical standpoint, **oxygen therapy**, the use of **Heliox**, and the administration of intravenous and aerosol **corticosteroids** consist of the emergent steps to reduce dyspnea

✓ Advantages

- rapid and effective
- not require laryngological skills

✗ Disadvantages

- decreased quality of life
- psychological and social problems
- continual postoperative care

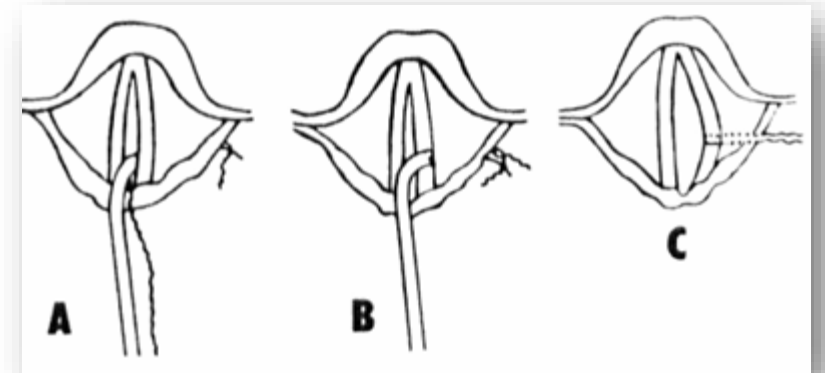
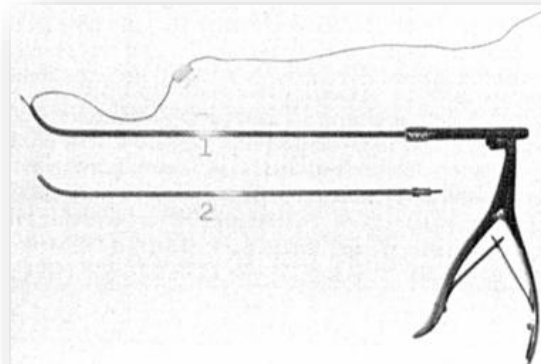


Reversible treatment – Laterofixation

- **Réthy Aurél (1922):**
positioning the arytenoid in abduction by fixing in the cricoarytenoid joint



- Kirchner (1979)
 - **Endoscopic** longitudinal resection of the TA muscle + **temporary laterofixation** using extra-endolaryngeal suture
- Lichtenberger (1979)
 - **EExLL**—endo-extralaryngeal laryngomicrosurgical lateralization



Type of surgery	Design	N	M/F	Age (A/M)	Tracheot.	Deca.	Timing	Follow-up	Outcomes	Effective rate
Laterofixation										
Geterud et al ²¹	Retrospective	11	4/7	65	NP	NP	NP	60 mo	Airway volume	Pre = postsurgery
Rovo et al ⁶⁵	Retrospective	15	1/14	33-73	2/15	2/2	6 mo ^b	17 mo	Airway volume	Post > presurgery
Rovo et al ¹⁹	Prospective	25	5/20	33-81	5/25	5/5	1-6 mo	25 mo	Dyspnea	96%
Leitersdorfer et al ¹¹	Retrospective	92	18/74	56	NP	NP	NP	2-6 mo	Airway volume	Post > presurgery
Hyodo et al ²²	Prospective	11	3/8	11	6/11	6/6	NP	2 mo	Airway volume	91%, post > presurgery
Ezzat et al ²⁰	Prospective	21	8/13	36	21/21	20/21	>1 wk	6 mo	Endoscopic findings	76%
Oysu et al ⁶⁶	Retrospective	13	0/13	52	0/13	NP	8 mo ^b	24 mo	Dyspnea	92%
Korkmaz et al ²³	Retrospective	47	3/44	NP	NP	NP	NP	19 mo	Dyspnea	94%
Wiegand et al ¹⁸	Retrospective	35	13/22	64	3/35	3/3	>1 wk	NP	Decannulation	100%

Decannulation rate: 97.0%

Respiratory Standpoint:

Adequate postoperative airway volume measurements

- forced inspiratory volume, forced expiratory volume 1s (FEV1), peak expiratory flow (PEF) Rate, endoscopic glottic findings

Type of surgery	Aspiration	Laryngeal Edema	Hematoma	Postop. Dyspnea	Fibrosis/ Scarring	PGS	Granuloma	Laterofixation Rupture	Suture Migration	Releasing Fixed cord	Surgical Revision
Laterofixation											
Geterud et al ²¹	1/11										
Rovo et al ⁶⁵	1/15	3/15									1/15
Rovo et al ¹⁹	1/25	4/25				1/25		3/25		9/25	1/25
Ezzat et al ²⁰							1/21		1/21		1/21
Oysu et al ⁶⁶		1/13						1/13			1/13
Korkmaz et al ²³		2/47	1/47								
Wiegand et al ¹⁸		6/35		3/35						2/35	

Complication:

- Laterofixation rupture/ releasing fixed fold (7.7%-36.0%)
- Postoperative laryngeal edema (7.7%-17.1%)
- Aspiration (4.0%-9.1%)

Revision rate: 4.0% to 7.7%

Treatment modality for BVFP	Indication	Pros	Cons
Laterofixation	Temporary management of the airway, with <u>expectation of recovery of laryngeal function or avoidance of tracheostomy</u>	Reversible; alternative to tracheostomy; greater improvement of airway, better voice quality, and <u>less revision rate than arytenoidectomy and cordotomy</u> ; may be performed with other endoscopic procedures	Complications such as hoarseness, need for adjustment, remedialization, dysphagia or aspiration

Permanent Surgery – Posterior Transverse Cordotomy

- aims at resection of **laryngeal soft tissues**, such as parts of the **vocal fold, the vocal ligament, or the thyroarytenoid (TA) muscle**
- From **“mucosa” to “submucosa”**
 - reducing scar formation and preserving phonatory function
- **Dennis and Kashima (1989)**

CARBON DIOXIDE LASER POSTERIOR CORDECTOMY FOR TREATMENT OF BILATERAL VOCAL CORD PARALYSIS

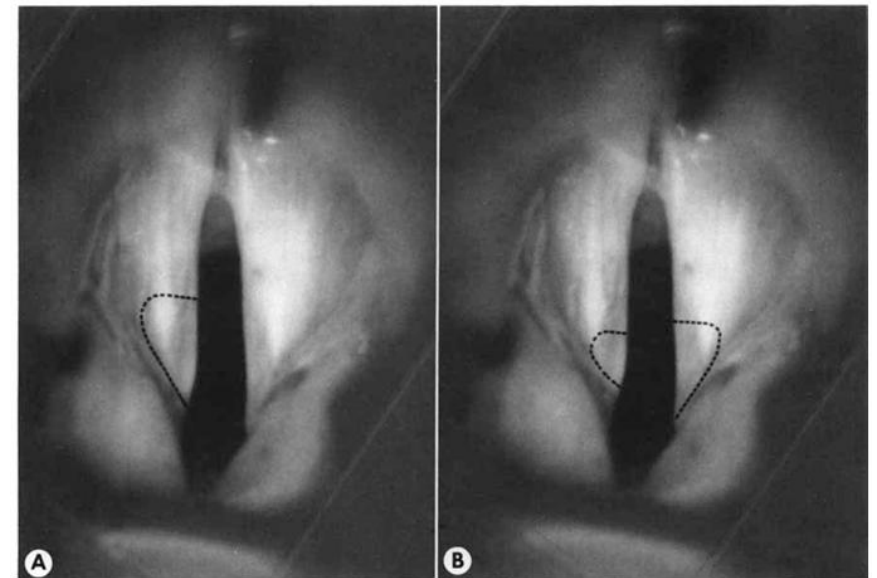
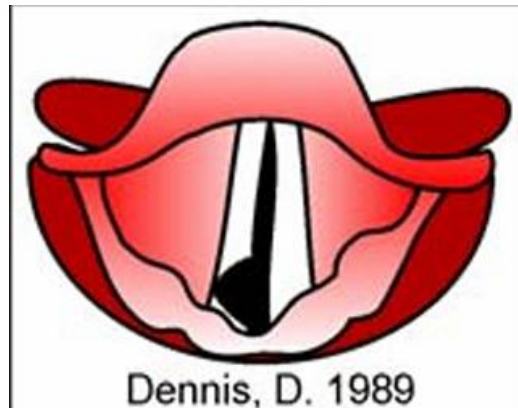


Fig 2. Views of larynx with dotted lines indicating lines of laser excision. A) Standard left posterior partial cordectomy. B) Standard right posterior partial cordectomy with lesser supplementary cordectomy on left.

Permanent Surgery – Posterior Transverse Cordotomy

Type of surgery	Design	N	M/F	Age (A/M)	Tracheot.	Deca.	Timing	Follow-up	Outcomes	Effective rate
Posterior unilateral cordotomy										
Laccourreye et al ⁴⁰	Retrospective	25	6/19	63	NP	NP	NP	5 years	Endoscopic findings	68%
Segas et al ⁴⁵	Retrospective	20	8/12	50	12/20	18/20	>3 mo	5 mo	Dyspnea	90%
Yagudin et al ⁴⁶	Prospective	21	0/21	56	21/21	21/21	>12 mo	3 mo	Airway volume	Post > presurgery
Oysu et al ⁴²	Retrospective	11	1/10	NP	2/11	2/2	>6 mo	6-15 mo	Exercise tolerance	Post > presurgery
Ozdemir et al ³⁴	Retrospective	66	8/58	48	7/66	NP	NP	40 mo	Airway restoration	88%
Khalil and Tawab ³⁹	Prospective	18	8/10	47	NP	NP	6 mo ^b	12 mo	Airway volume	72%
Ozturk et al ⁴³	Controlled	30	12/18	53	NP	NP	6 mo ^a	6 mo	Airway volume	Post > presurgery
Mohamed et al ⁴¹	RCT	20	4/16	50	2/20	NP	12 mo ^b	12 mo	Dyspnea score	Post > presurgery
Rashid et al ⁴⁴	Retrospective	34	10/24	39	NP	NP	6 mo ^b	6 wk	Dyspnea	Post > presurgery

Decannulation rate: 95.1%

Respiratory Standpoint:

- respiratory/dyspnea score (subjective)
- peak expiratory or inspiratory flow, FEV1, or maximum phonation time (MPT) >>improved

Type of surgery	Design	N	M/F	Age (A/M)	Tracheot.	Deca.	Timing	Follow-up	Outcomes	Effective rate
Posterior bilateral cordotomy										
Khalifa ⁴⁷	Prospective	22	8/14	41	18/22	12/22	>1 mo	1-2 mo	Decannulation	54%
Dursun and Gökcan ⁷⁵	Retrospective	22	8/14	45	6/22	NP	NP	12 mo	Dyspnea score	95%
Bajaj et al ³⁶	Retrospective	9	3/6	27-85	3/9	3/3	12 mo ^a	3-28 mo	Dyspnea and voice	100%-78%
Asik et al ³⁵	Prospective	11	2/9	46	0/11	0/0	48 mo ^b	2 mo	Airway volume	Post > presurgery
Basterra et al ³⁷	Retrospective	18	3/6	27-85	7/18	7/7	NP	2-5 years	Airway volume	74%-91%
Benninger et al ³⁸	Retrospective	15	4/11	57	3/15	2/3	NP	18 mo	Stridor	83%
Karkos et al ⁶²	Prospective	12	2/10	56	12/12	12/12	12 mo ^b	24 mo	Decannulation	100%

Decannulation rate: 76.6%

Respiratory Standpoint:

- patient-reported or physician perception of dyspnea, MPT, forced vital capacity, PIF, FEV1, VO2 max >>improved

Permanent Surgery – Posterior Transverse Cordotomy (Unilateral)

Type of surgery	Aspiration	Laryngeal Edema	Hematoma	Postop. Dyspnea	Fibrosis/ Scarring	PGS	Granuloma	Laterofixation Rupture	Suture Migration	Releasing Fixed cord	Surgical Revision
Posterior unilateral cordotomy											
Laccourreye et al ⁴⁰	0/25	0/25	0/25	0/25			0/25	-	-	-	6/25
Segas et al ⁴⁵		8/20					7/20	-	-	-	9/20
Yagudin et al ⁴⁶							3/21	-	-	-	0/21
Oysu et al ⁴²	0/25	0/25	0/25	0/25			0/25	-	-	-	2/11
Ozdemir et al ³⁴		7/66		4/66			4/66	-	-	-	12/66
Khalil and Tawab ³⁹	1/18						3/18	-	-	-	
Ozturk et al ⁴³							6/30	-	-	-	0/30
Rashid et al ⁴⁴								-	-	-	6/34

Revision rate: **0 - 45%**

Aspiration: **5.6%** (Khalil)

Voice Quality Outcome: **controversial**

- worsening of perceptual voice quality
- No significant differences in pre- to postoperative voice handicap index (VHI), and acoustic measurements.

Permanent Surgery – Posterior Transverse Cordotomy (Bilateral)

Type of surgery	Aspiration	Laryngeal Edema	Hematoma	Postop. Dyspnea	Fibrosis/ Scaring	PGS	Granuloma	Laterofixation Rupture	Suture Migration	Releasing Fixed cord	Surgical Revision
Posterior bilateral cordotomy											
Khalifa ⁷⁴					4/22			-	-	-	4/22
Dursun and Gökcan ⁷⁵								-	-	-	
Bajaj et al ³⁶				1/9				-	-	-	0/9
Asik et al ³⁵	0/11	0/11	0/11	0/11			0/11	-	-	-	0/11
Basterra et al ³⁷								-	-	-	
Benninger et al ³⁸							4/15	-	-	-	7/15
Karkos et al ⁶⁹								-	-	-	

Revision rate: 0 – 46.7%

- Granuloma
- fibrosis/scaring of the sectioned vocal cord

Voice Quality Outcome: more controversial

- Worsening: VHI, grade, roughness, breathiness, asthenia, strain
- Unchanged voice quality outcomes
- Improvements

Treatment modality for BVFP	Indication	Pros	Cons
Cordotomy	<u>Permantant management</u> of BVFP; patients who want to be decannulated or avoid tracheostomy	Quick, effective enlargement of glottis to return breathing through mouth without dyscosmesis; can be combined with arytenoidectomy; more cost-effective than tracheostomy; <u>less tendency for aspiration than arytenoidectomy</u>	Irreversible; deterioration of voice; scar or granuloma formation; aspiration; may need revision surgery

Permanent Surgery – Total Arytenoidectomy

- **Removal of arytenoid cartilage (i.e., arytenoidectomy)** is a permanent and irreversible surgical procedure
- **Expanded glottal inlet in its transverse axis**, providing a larger airway for respiration

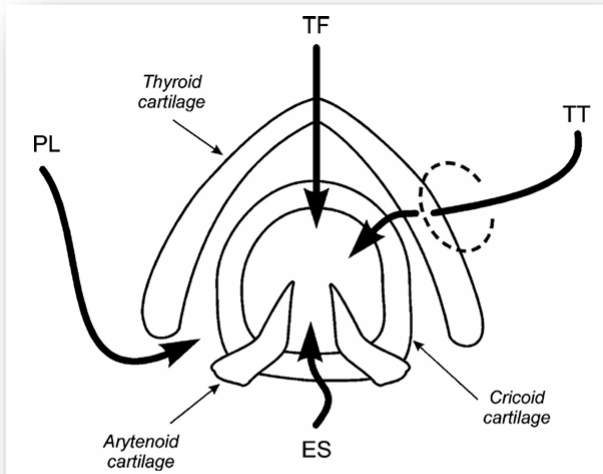


Fig. 1 Approaches used for surgery for BVFP: *TF* median thireofissure (sometimes with splitting of the cricoid cartilage—then laryngofissure); *TT* lateral transthyroid—through a window or after partial resection of the thyroid lamina; *PL* paralaryngeal—behind the posterior margin of the thyroid cartilage; *ES* endoscopic. Most of the techniques based on *TT* or *PT*-approach allow preserving the integrity of the mucosa

- **Thornell (1949)**

- first endolaryngeal arytenoidectomy through the **endoscopic approach**

- **Ossoff (1983)**

- first described the total arytenoidectomy procedure **using the CO2 laser** endoscopically

Permanent Surgery – Total Arytenoidectomy

Type of surgery	Design	N	M/F	Age (A/M)	Tracheot.	Deca.	Timing	Follow-up	Outcomes	Effective rate
Total uni/bilateral arytenoidectomy										
Ossof et al ⁴⁹	Retrospective	11	1/10	59	6/11	10/11	NP	6-36 mo	Decannulation	91%
Szmeja and Wójtowicz ⁵²	Retrospective	30	NP	47	3/30	3/3	NP	NP	Dyspnea	100%
Li et al ⁶³	Prospective	9	0/9	53	NP	NP	NP	10 mo	Airway index	Post > presurgery
Misiolek et al ⁵⁴	Prospective	36	3/33	52	22/36	35/36	NP	1 mo	Airway volume	Post > presurgery
Yilmaz et al ⁵	Retrospective	50	9/41	50	40/50	37/40	NP	1 mo	Dyspnea	Post > presurgery
Hu et al ⁵¹	Retrospective	14	8/6	44	14/14	13/14	NP	6 mo	Decannulation	93%

Decannulation rate: **95.3%**

Respiratory Standpoint: Significant improvements

- patient reported dyspnea, FEV1, vital capacity, and PEF

Permanent Surgery – Total Arytenoidectomy

Type of surgery	Aspiration	Laryngeal Edema	Hematoma	Postop. Dyspnea	Fibrosis/ Scaring	PGS	Granuloma	Laterofixation Rupture	Suture Migration	Releasing Fixed cord	Surgical Revision
Total arytenoidectomy											
Ossaf et al ⁷¹						1/11		-	-	-	
Szmeja and Wójtowicz ⁵²					1/30			-	-	-	1/30
Li et al ⁷⁰	0/9	0/9	0/9	0/9			0/9	-	-	-	
Misiolek et al ⁵⁴								-	-	-	
Yilmaz ⁵		1/50		1/50				-	-	-	3/50
Hu et al ⁵¹					1/14			-	-	-	1/14

Revision rate: 7 %

- development of scaring

Aspiration: 50 % (Eckel HE)

Voice Quality Outcome: Most worsened

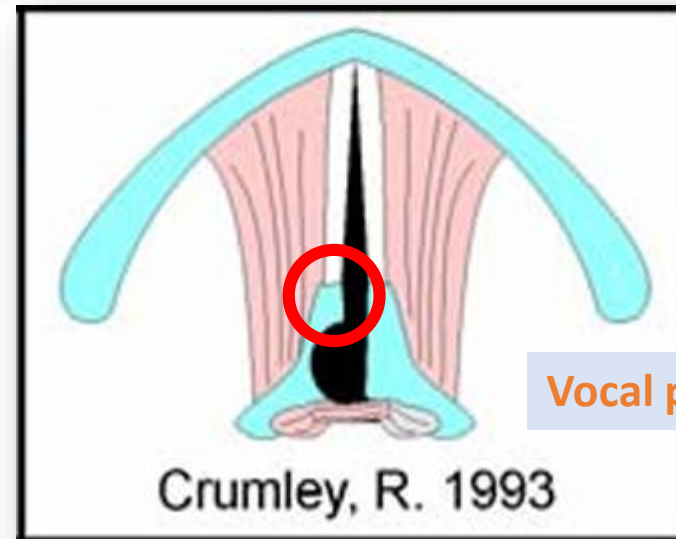
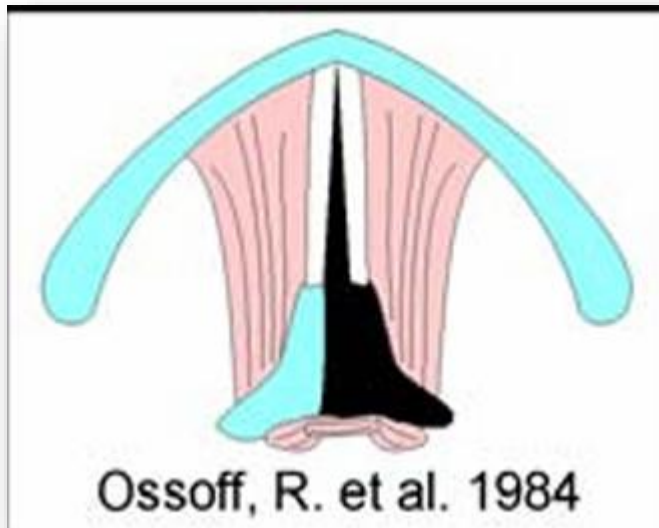
- Worsening of MPT and acoustic measurements (Motta)
- Postoperative dysphonia (Anand)
- VHI-30, MPT, and acoustic parameters significantly worsened (Yilamaz)

Permanent Surgery – Partial Arytenoidectomy

- Crumley (1993)

ENDOSCOPIC LASER **MEDIAL ARYTENOIDECTOMY** FOR
AIRWAY MANAGEMENT IN BILATERAL LARYNGEAL PARALYSIS

ROGER L. CRUMLEY, MD
ORANGE, CALIFORNIA



Use of an **endoscopic plasma coblator** instead of laser induced **less scar formation by avoiding thermal damage** to surrounding tissues

Permanent Surgery – Partial Arytenoidectomy

Type of surgery	Design	N	M/F	Age (A/M)	Tracheot.	Deca.	Timing	Follow-up	Outcomes	Effective rate
Partial uni/bilateral arytenoidectomy										
Crumley ⁴⁷	Retrospective	8	NP	NP	6/8	2/6	NP	6 mo	Exercise tolerance	100%
Gorphe et al ⁵⁰	Prospective	20	7/13	52	5/20	5/5	NP	3 mo	Dyspnea	100%
Yilmaz et al ⁵³	RCT	20	5/15	52	4/20	NP	NP	12 mo	Airway volume	Pre = postsurgery
Yilmaz ⁴⁸	Prospective	64	8/56	52	9/50	9/9	NP	12 mo	Airway restoration	88%

Decannulation rate: 83%

Respiratory Standpoint: Significant improvements

- exercise tolerance, patient-reported dyspnea, FEV1, FIV, airway volume, airway resistance, or physician reported airway restoration

Permanent Surgery – Partial Arytenoidectomy

Type of surgery	Aspiration	Laryngeal Edema	Hematoma	Postop. Dyspnea	Fibrosis/ Scaring	PGS	Granuloma	Laterofixation Rupture	Suture Migration	Releasing Fixed cord	Surgical Revision
Partial uni/bilateral arytenoidectomy								-	-	-	
Crumley ⁴⁷	0/8	0/8	0/8	0/8			0/8	-	-	-	0/8
Gorphe et al ⁵⁰							1/20	-	-	-	5/20
Yilmaz et al ⁵³								-	-	-	
Yilmaz ⁴⁸								-	-	-	8/64

Revision rate: 14.1 %

- persistent dyspnea after surgery

Complications: rare

- postoperative granuloma

Voice Quality Outcome: Controversial

- not worsened according to patients
- worsening of VHI, MPT, voice intensity, and acoustic measurements (Yilmaz)
- No significant difference in VHI and acoustic measurements (Gorphe)

Treatment modality for BVFP

Indication

Pros

Cons

Arytenoidectomy

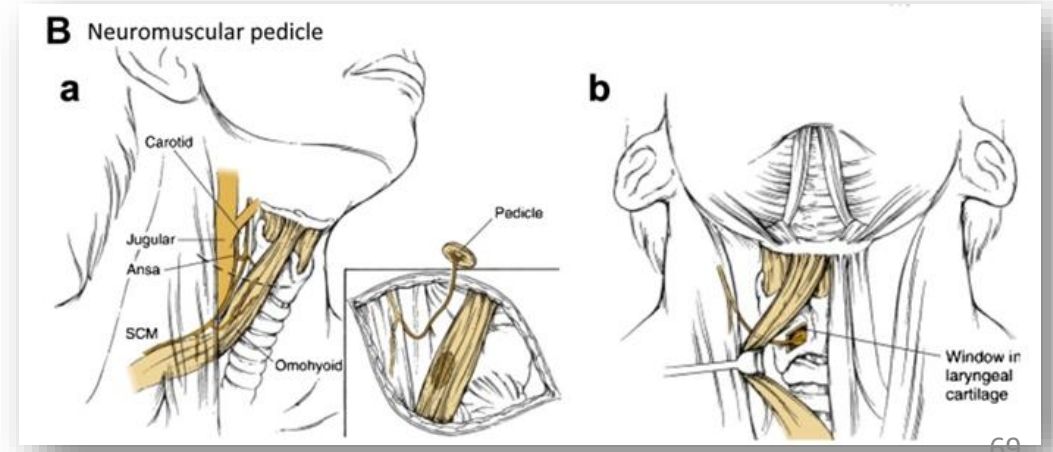
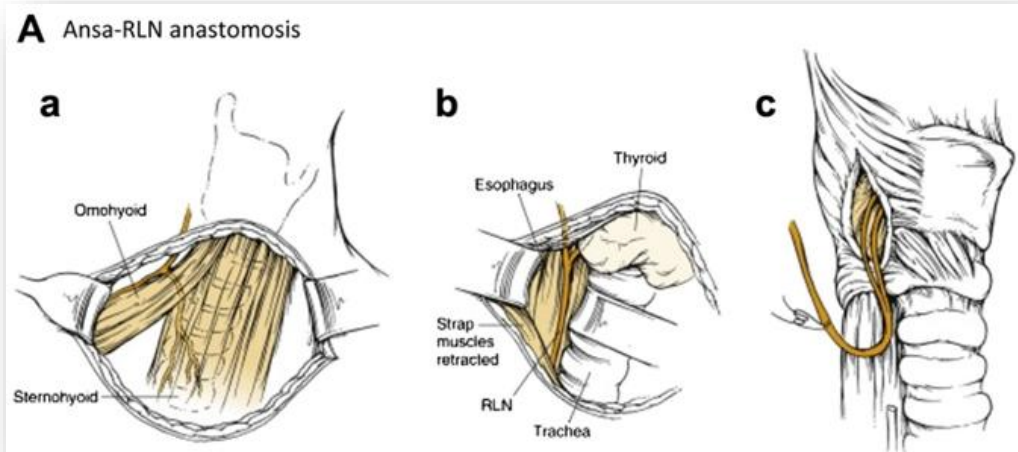
Permantant management of BVFP; patients who want to be decannulated or avoid tracheostomy

Quick, effective enlargement of glottis to return breathing through mouth without dyscosmesis; can be combined with cordotomy; more cost-effective than tracheostomy

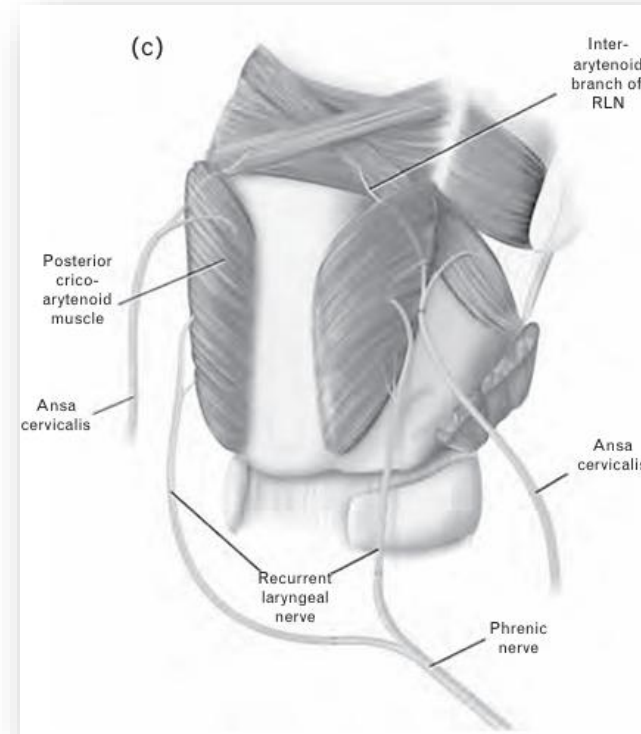
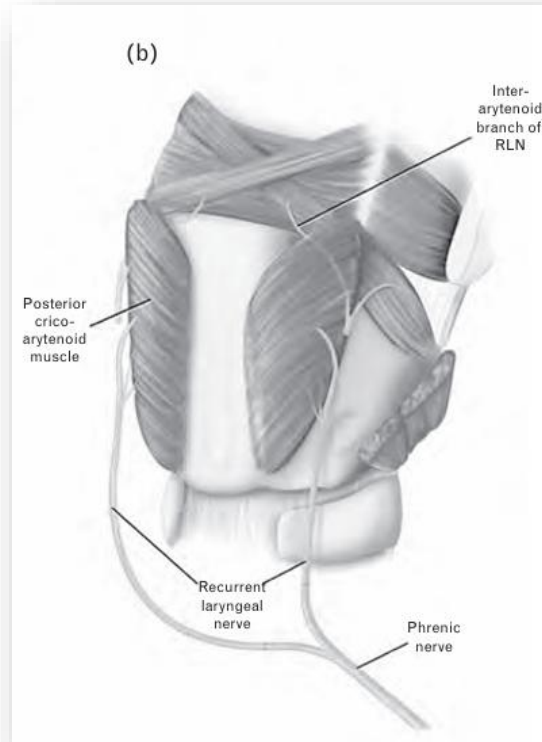
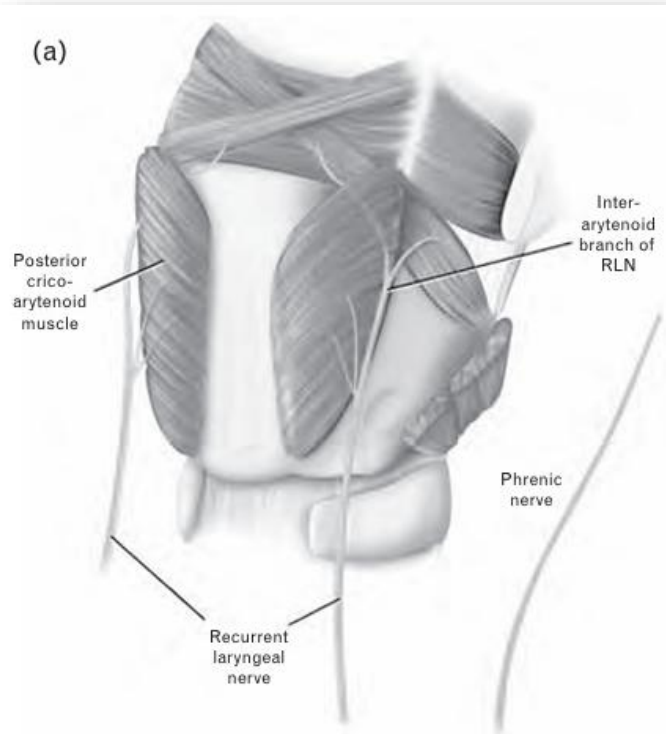
Irreversible; deterioration of voice; scar or granuloma formation; aspiration; may need revision surgery

Permanent Surgery – Reinnervation

- Resection-based procedures enlarge the airway but **fail to restore dynamic laryngeal function**
- Reinnervation aims to **re-establish vocal fold abduction** by targeting the posterior cricoarytenoid (PCA) muscle
- Although primarily developed for UVFP, reinnervation may be applicable in selected BVFP cases



Permanent Surgery – Reinnervation

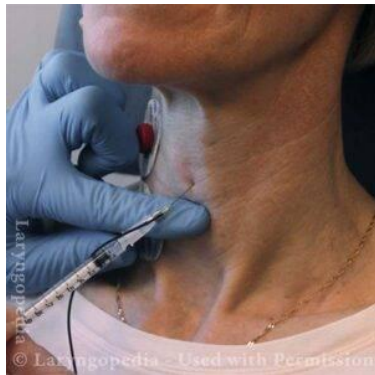

Decannulation rate: 83% / 89.7% (Li et al)

Recovery of vocal cord movement: 93% (Li et al)

Botulinum Toxin Injection

- Botulinum toxin injections are commonly performed in cases of **aberrant reinnervation of the adductor muscles by inspiratory motoneurons** to improve the glottic opening.



Synkinesis: The simultaneous contraction of antagonist muscles is called synkinesis.

Treatment modality for BVFP	Indication	<i>Pros</i>	<i>Cons</i>
Botox injection	<u>Temporary management of synkinetic larynx</u>	Less invasive; <u>short-term improvement in ventilation; little effect on voice or swallowing</u>	<u>Repeated injections</u> are required; human trials are limited

Other treatment options for BVFP

Treatment modality for BVFP	Indication	<i>Pros</i>	<i>Cons</i>
Reinnervation	Patients that have non-atrophic viable muscles maintained through synkinetic reinnervation	A promising procedure that may allow return of spontaneous vocal fold abduction; non-destructive and doesn't impair adductory functions	Technically more difficult; human trials are limited; potential diaphragmatic paralysis
Laryngeal pacing	Patients that have <u>non-atrophic viable</u> muscles maintained through synkinetic reinnervation	Greater ventilatory improvement reported than any other approach; no compromise of voice or swallowing	Still experimental with only 2 human trials; complicated procedure; more expensive than enlargement or lateralization approaches; device has to be replaced every 5–10 years
Neuromodulation	Recently injured RLNs; <u>muscles still denervated and nerve regenerating prior to synkinetic reinnervation</u>	From canine studies, electrical neuromuscular conditioning promotes selective reinnervation of muscles, minimizes synkinesis and restores ventilation to normal	Experimental; no human trial
Gene therapy	BVFP caused by neurodegenerative diseases	Less invasive; could promote nerve regeneration and prevent muscle atrophy	Experimental; no human trial; not effective in preventing synkinesis; neuronal damage by viral vectors
Stem cell therapy	BVFP caused by neurodegenerative diseases	Could promote nerve regeneration and prevent muscle atrophy	Experimental; no human trial; not effective in preventing synkinesis; issues associated with isolation, culture and survival of stem cells

Summary

Tracheostomy Acute dyspnea; temporary management of BVFP

Arytenoidectomy Permanent management of BVFP; patients who want to be decannulated or avoid tracheostomy

Cordotomy Permanent management of BVFP; patients who want to be decannulated or avoid tracheostomy

Laterofixation Temporary management of the airway, with expectation of recovery of laryngeal function or avoidance of tracheostomy

Reinnervation Patients that have non-atrophic viable muscles maintained through synkinetic reinnervation

Laryngeal pacing Patients that have non-atrophic viable muscles maintained through synkinetic reinnervation

Botox injection Temporary management of synkinetic larynx

Neuromodulation Recently injured RLNs; muscles still denervated and nerve regenerating prior to synkinetic reinnervation

Gene therapy BVFP caused by neurodegenerative diseases

Stem cell therapy BVFP caused by neurodegenerative diseases

Decannulation rate

T: 95.3%
P: 83%

U: 95.1%
B: 76.6%

97.0%

83-89.7% (Li et al)

Respiratory

Sig. Improved

Improved

Adequate

Voice

Most worsened

Controversial

Aspiration

T: 50%/ NM

5.6% (Khalil)

4.0-9.1%

Revision rate

T: 7%
P: 14.1%

0-45%

4.0-7.7%

Thank you!